

УДК 616.728.3:616.758-003.8]-073.763.5](045)=111

DOI: <http://dx.doi.org/10.15674/0030-59872024482-85>

Partial resection as a treatment for mucoid degeneration of the anterior cruciate ligament: a case report

Krishna Amith Kumar, Ranjith Narayan

MBBS, MS Orthopaedics, Department of Orthopaedics, Aster Hospital Mankool, Dubai. UAE

Mucoid degeneration of the anterior cruciate ligament (MDACL) is an uncommon degenerative disease. Objective. To present a case of mucoid degeneration of the anterior cruciate ligament diagnosed using Magnetic Resonance Imaging and treated with arthroscopic resection. Methods. In our case report, we examined the medical history of a patient and developed a list of clinical manifestations observed in our case. Magnetic Resonance Imaging is the most efficient approach for differentiating between mucoid degeneration of the anterior cruciate ligament and other knee joint disorders. Results. Our patient presented with a 3-month history of right knee discomfort. The age of the patient was 28 years old. There were no indications of edema or instability, although his knee flexion ranged from 0°–100°. We diagnosed MDACL using MRI and arthroscopic findings. In T2-weighted images, the ACL exhibited an abnormally elevated signal with a mass-like structure of its fibres. In T2-weighted coronal images, the association between the fibres and the aberrant soft tissue was discernible. Based on normal preoperative findings, this case was diagnosed and presented. Magnetic Resonance Imaging revealed a celery-stalk-like appearance of the anterior cruciate ligament suggesting mucoid degeneration of the anterior cruciate ligament, with additional joint effusion. Upon arthroscopy, the anterior cruciate ligament appeared homogenous and hypertrophied with a bulbous lateral portion. The yellow and sclerotic lesions on the lateral portion of the anterior cruciate ligament were excised precisely. Conclusions. In the present case, arthroscopic resection of a degenerating ACL that is causing pain demonstrated good results. In some cases it could lead to subjective progressive laxity after the surgery. The prognosis is dependent on the age of the patient and what other injuries they might have. MDACL should be considered when there is unusual discomfort in the spine and limited flexing. MRI and arthroscopy both pointed to the same diagnosis.

Мукоїдна дегенерація передньої схрещеної зв'язки (МДПСЗ) є рідкісним дегенеративним захворюванням. Мета. Навести випадок мукоїдної дегенерації передньої схрещеної зв'язки (ПСЗ), діагностований за допомогою магнітно-резонансної томографії (МРТ), який лікували за допомогою артроскопічної резекції. Методи. У нашому клінічному випадку ми вивчили історію хвороби пацієнта та розробили перелік клінічних проявів, які спостерігали. МРТ-дослідження є найбільш ефективним підходом для диференціації між МДПСЗ та інших захворювань колінного суглоба. Результати. Наш пацієнт звернувся з 3-місячним анамнезом дискомфорту в правому коліні. Вік пацієнта становив 28 років. Не було жодних ознак набряку або нестабільності, хоча згинання коліна коливалося від 0°–100°. Ми діагностували МДПСЗ за допомогою МРТ та артроскопічних даних. На зображеннях ПСЗ демонстрував аномально підвищений сигнал із масоподібною структурою своїх волокон, а на корональних відбитках було помітно зв'язок між волокнами та абераційною м'якою тканиною. На основі передопераційних даних цей випадок було діагностовано. МРТ виявило, що ПСЗ зазнала змін, що свідчить про МДПСЗ із додатковим випотом у суглобі. За артроскопії ПСЗ виявилось, що зв'язка гомогенна та гіпертрофована у латеральному відділі. Жовті та склеротичні ураження на бічній частині ПСЗ було видалено. Висновки. У даному випадку артроскопічна резекція дегенеративної ПСЗ, яка викликає біль, продемонструвала хороші результати. Проте в деяких випадках це може призвести до суб'єктивного прогресуючого незрошення після операції. Прогноз залежить від віку пацієнта і від того, які ще травми в нього можуть бути. МДПСЗ слід розглядати, коли відчувається дискомфорт у хребті та обмежене згинання. МРТ і артроскопія мали однаковий діагноз. Ключові слова. Передня схрещена зв'язка, артроскопія, магнітно-резонансна томографія, мукоїдна дегенерація.

Keywords. Anterior cruciate ligament, arthroscopy, magnetic resonance imaging, mucoid degeneration

Introduction

Mucoid degeneration of the anterior cruciate ligament (MDACL) is an uncommon degenerative disease. When the mucilaginous material inside the anterior cruciate ligament (ACL) becomes dislodged, pain, and limited knee motion may arise [1]. Although cysts of the ACL were first described in 1924 [2], the condition has been rare and underexplored since then. The occurrence of this lesion ranges between 0.2 and 1.2 % [3]. Because the origins of MDACL remain unclear, various hypotheses have been proposed to explain it. MDACL can have either a degenerative or traumatic root. The «synovial theory», in which synovium fills a herniated pouch made of synovium, has been discussed as another possibility [2]. MDACL differs from ACL synovial cysts because the mucoid tissue is not enclosed within a cyst [4]. On magnetic resonance imaging (MRI), the prevalence of MDACL was reported to be between 1.8 to 5.3 %. In most individuals, MDACL is asymptomatic [5]. Individuals with symptomatic MDACL typically exhibit posterior knee discomfort and difficulties in flexing and extending the knee [6].

A celery-stalk-like sign in the MRI indicates MDACL, that should be further confirmed by biopsy of the tissue and histological analysis. Bergin et al. [7], outlined a typical MRI criterion for MDACL: high signal strength in both T1, T2 sequences, an enlarged ACL, and continuous ACL fibres in T2 sequences. Arthroscopic criteria [8] for a diagnosis of ACL tears included the presence of continuous ACL fibres, an increase in ACL volume, the presence of yellowish-colored material upon palpation, and the absence of synovial lining of the ACL.

MDACL is initially treated using non-surgical methods including non-steroidal anti-inflammatory drugs (NSAIDs) and physiotherapy. Arthroscopic debridement, followed by partial or complete resection of the ACL occasionally paired with ACL repair, is one of the different surgical treatments used by surgeons. MDACL treatment outcomes and the associated risk of instability are still unknown. A recent systematic review compiled and analysed existing treatment options, demonstrated arthroscopic debridement to be beneficial for pain, improving range of motion, and functional outcomes of MDACL patients [9]. In the present case, we demonstrate MRI findings of MDACL and its subsequent management using arthroscopic resection.

Objective: to present a case of mucoid degeneration of the anterior cruciate ligament diagnosed us-

ing Magnetic Resonance Imaging and treated with arthroscopic resection.

Material and methods

A 28-year-old man with no history of significant trauma or surgery presented to our hospital with right knee pain and painful restricted movement over the past three months. Physical examination revealed no edema, patellar ballottement, or instability. Indications of mild effusion were detected in the patellofemoral joint area, suprapatellar bursa, para-condylar recess, and around the cruciate ligament.

MRI findings

A heightened intra-ligamentous signal with a heterogeneous intensity and an undistorted external meniscus fracture was observed in the right knee MRI (Fig. 1, a, b). We found a globular-wedge-shaped signal alteration of grade 2c that did not extend to the anterior horn of the lateral meniscus. The ACL is fibrous and robust. T1 intermediate and PDFS (proton density-fat saturate) hyperintense material were found interposed among the fibres of the ACL, resulting in a celery-stalk look of the ACL, suggestive of MDACL. Additionally, some modest joint effusion was visible.

Sagittal PD (proton density), T1, and TSE (turbo-spin-echo) T2 weighted scans of the right joint were obtained for the follow-up MRI report. STIR (short tau inversion recovery) and PD coronal, T2 axial, and WATS (Water selective excitation; gradient) axial images were correlated. With intrasubstance T1 intermediate and PDFS hyperintense signal, the ACL resembled a stalk of celery. There was no discontinuity in the fibres. The anterior horn of the lateral meniscus displayed an aberrant signal intensity in the shape of a globular wedge that did not extend to the articular surface, indicating a grade 2c signal alteration.

Intraoperative findings

The patient's medical history and MRI results indicated an intra-ligamentous cyst of the ACL. Therefore, we performed an arthroscopy. During arthroscopy, it was determined that the ACL was homogenous, hypertrophied, and its lateral portion was notably bulbous. It filled the whole intercondylar notch that was exceptionally taut, approaching 90° of flexion. The ACL fibres were intermingled with a homogeneous yellowish mass (Fig. 2, a). The lack of ligamentum mucosa was evident. In extension, the ACL's posterolateral component protruded into the lateral compartment (Fig. 2, b). No additional knee pathology was observed. We removed the homogeneous posterolateral ACL mass that was impinging on the lateral compartment, which revealed a yellowish mass inside the ACL's material (Fig. 2, c, d).

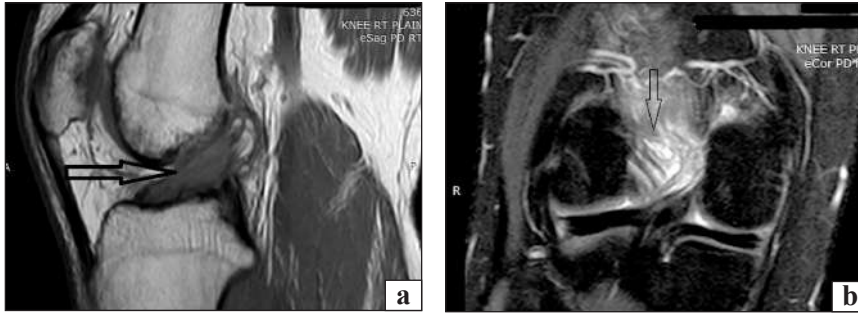


Fig. 1. (a) MRI reveals an aberrant signal in a bulky ACL on both T1-weighted, (b) T2-weighted imaging

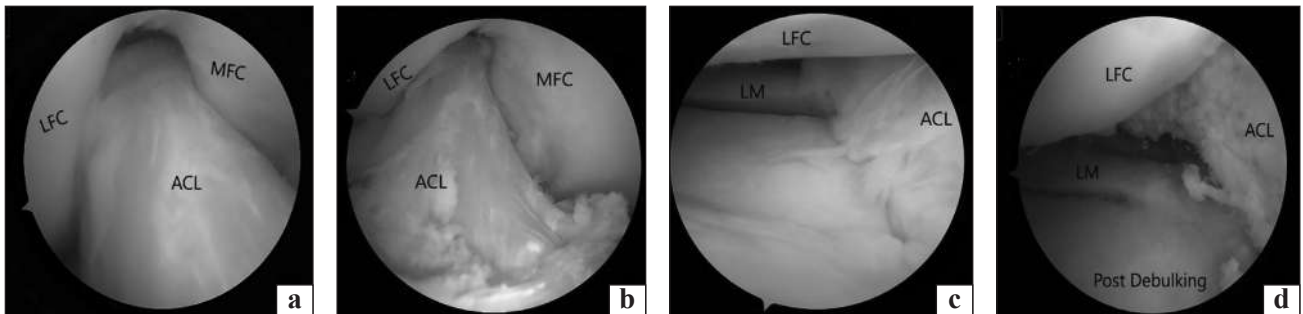


Fig. 2. The ACL appears homogeneous, hypertrophied, yellowish, and fills the notch with absent ligamentum mucosum on arthroscopic examination (a), arthroscopic image of the ACL impinging in the lateral compartment during knee extension (b), yellowish mucoid mass in the intercondylar notch and in ACL (c), post-debulking of ACL. Abbreviations: MFC — medial femoral condyle; LFC — lateral femoral condyle; LM — lateral meniscus (d)

We used a longitudinal incision to conduct a futile search for mucus discharge from the ACL. On the lateral portion of the ligament, we noticed yellow and sclerotic lesions, which we excised precisely.

Results and Discussion

The clinical and radiological features of MDACL have been inadequately reported in previous literature, rendering the appropriate management plan for the condition ambiguous [10]. The results of a previously conducted study reported that the predominant management technique for MDACL was partial debridement, or total resection with ACL reconstruction, and conservative management as alternative approaches. However, there remains no clear consensus on the most effective method for managing the condition [11].

Our patient presented with a 3-month history of right knee discomfort. The age of the patient was 28 years which contrasted the results of a previously conducted study wherein the patients with ACL mucoid degeneration had a mean age of 50.4 years which is much higher than that of the present study [12]. There were no indications of edema or instability, although his knee flexion ranged from 0°–100°. We diagnosed MDACL using MRI and arthroscopic findings. In T2-weighted images, the ACL exhibited an abnormally elevated signal with a mass-like structure of its fibres. In T2-weighted coronal images, the association between the fibres and the aberrant

soft tissue was discernible. In cases treated with partial debridement, the remaining ACL fibres may be diseased and lack sufficient mechanical strength to prevent excessive knee motion, potentially leading to eventual tearing — an important drawback of this approach. Although many authors believe that complete ACL resection could increase the risk of knee instability, a study by Himpe N. et al. found that all patients who underwent complete arthroscopic resection of the ACL without subsequent ACL reconstruction reported the same or improved subjective knee stability [13]. To study this clinically, we conducted an arthroscopic ACL excision, which resulted in total symptom alleviation and complete flexion.

In a retrospective study of MDACL in ten individuals by McIntyre et al. [8], an ACL tear on MRI was identified but their ligaments were intact during arthroscopy. The authors stated that «Mucoid degeneration and an intact ACL can be suspected when an apparently thicker and ill-defined ligament with increasing signal intensity on all sequences is observed in a patient with a clinically intact ligament».

In the present case, ACL seemed homogeneous, hypertrophied, taut, and bulbous during arthroscopy. The significance of the absence of the ligamentum mucosum is uncertain. The ACL was comprised of typical ACL fibres mixed with a mass of yellowish homogeneous tissue that looked to be augment-

ing the ACL's volume. This could explain the ACL's taut and bulbous appearance, with the increased volume of ACL being responsible for these patients' symptoms, as reported by Narvekar A. et. al [14]. They reduced the ligament's volume and tension by excising the yellowish mucoid tissue from its substance while keeping the attachment intact with the femur and tibia. This decrease in volume and tension inside the ligament was responsible for the considerable pain alleviation immediately following surgery. With notchplasty and debulking, the impingement of the ligament on the roof and lateral wall of the notch was eliminated [14].

Our patient exhibited full painless and stable knee motion at 12 months. This was similar to the results of a previous study wherein 36.4 % of the patients with ACL mucoid degeneration obtained complete alleviation of pain [13]. MRI can help diagnose and plan ACL mucoid degeneration surgery. Preoperatively, these symptoms can diagnose this condition. Partial ACL excision relieves discomfort and increases range of motion without instability [12]. A previously conducted study compared conservative treatment with arthroscopic surgery and the results showed that both treatments were successful at reducing pain among the patients, arthroscopic surgery being the more desirable option due to its non-invasive approach [10].

In the present case, arthroscopic resection of a degenerating ACL that is causing pain demonstrated good results. In some cases it could lead to subjective progressive laxity after the surgery. The prognosis is dependent on the age of the patient and what other injuries they might have. MDACL should be considered when there is unusual discomfort in the spine and limited flexing. MRI and arthroscopy both pointed to the same diagnosis.

Conflict of interest. The authors declare no conflict of interest.

References

- Pandey, V., Suman, C., Sharma, S., Rao, S. P., Kiran Acharya, K., Sambaji C. (2014). Mucoid degeneration of the anterior cruciate ligament: Management and outcome. *Indian Journal of Orthopaedics*, 48(2), 197-202. doi: 10.4103/0019-5413.128765.
- El Kadi, K. I., Marcaillou, F., Blanc, S., Salloum, B., Dimontagliari, C., Boutayeb, F. (2013). Mucoid degeneration of the anterior cruciate ligament: a case report. *Pan African Medical Journal*, 15, 59. doi: 10.11604/PAMJ.2013.15.59.2534.
- Kim, M. G., Kim, B. H., Choi, J. A., Lee, N. J., Chung, K. B., Choi, Y. S., Cho, S., Lim, H. C. (2001). Intra-articular ganglion cysts of the knee: clinical and MR imaging features. *European Radiology*, 11(5), 834-840. doi: 10.1007/s003300000713.
- Lintz, F., Pujol, N., Dejour, D., Boisrenoult, P., Beaufils P. (2010). Anterior cruciate ligament mucoid degeneration: selecting the best treatment option. *Orthopaedics & Traumatology: Surgery & Research*, 96(4), 400-406. doi: 10.1016/j.otsr.2010.02.008.
- Wang, J. H., Jangir, R. R. (2013). Mucoid Degeneration of Posterior Cruciate Ligament with Secondary Impingement of Anterior Cruciate Ligament: A Rare Case Report. *Journal of Orthopaedic Case Reports*, 5(4), 44-46. doi: 10.13107/jocr.2250-0685.343.
- Cha, J. R., Lee, C. C., Cho, S. Do., Youm, Y. S., Jung, K. H. (2013). Symptomatic mucoid degeneration of the anterior cruciate ligament. *Knee Surgery, Sports Traumatology, Arthroscopy*, 21, 658-663. <https://doi.org/10.1007/s00167-012-1991-9>
- Bergin, D., Morrison, W. B., Carrino, J. A., Nallamshetty, S. N., Bartolozzi, A. R. (2004). Anterior cruciate ligament ganglia and mucoid degeneration: coexistence and clinical correlation. *American Journal of Roentgenology*, 182(5), 1283-1287. doi: 10.2214/ajr.182.5.1821283.
- McIntyre, J., Moelleken, S., Tirman, P. (2001). Mucoid degeneration of the anterior cruciate ligament mistaken for ligamentous tears. *Skeletal Radiology*, 30(6), 312-315. doi: 10.1007/s002560100336.
- Sweed, T., Mussa, M., El-Bakoury, A., Geutjens, G., Metcalfe, A. (2021). Management of mucoid degeneration of the anterior cruciate ligament: a systematic review. *Knee Surgery & Related Research*, 33(1), 26. doi: 10.1186/S43019-021-00110-6.
- Luo, J., Zhou, M., Luo, X., Luo, P., Yang, Z., Li, R., Duan, C., Feng, X., Wu, T. (2024). Mucoid Degeneration of the Anterior Cruciate Ligament: Characteristics and Conservative Management. *Journal of Knee Surgery*, 37(3), 198-204. doi: 10.1055/a-2037-6138.
- Vivekanantha, P., Diao, Y. D., Kay, J., Hoshino, Y., Nagai, K., de Sa, D. (2023). Partial debridement is the most commonly reported treatment option for mucoid degeneration of the anterior cruciate ligament: a systematic review. *Knee Surgery, Sports Traumatology, Arthroscopy*, 31(10), 4265-4275. doi: 10.1007/s00167-023-07479-9.
- Morice A, Coupry A, Lintz F, Robert H. (2013). Reduction plasty for hypertrophic anterior cruciate ligament mucoid degeneration: Clinical and knee laxity outcomes in 23 cases. *Orthop Traumatol Surg Res*, 99(6), 693-697.
- Himpe, N., Berger, P., Vandenneucker, H. (2020). Mucoid degeneration of the anterior cruciate ligament. Complete resection as equivalent treatment to partial resection. *Acta Orthopaedica Belgica*, 86(2), 272-279.
- Narvekar, A., Gajjar, S. (2004). Mucoid degeneration of the anterior cruciate ligament. *Arthroscopy: The Journal of Arthroscopic & Related Surgery*, 20(2), 141-146. doi: 10.1016/j.arthro.2003.11.030.

The article has been sent to the editors 15.10.2024

PARTIAL RESECTION AS A TREATMENT FOR MUCOID DEGENERATION OF THE ANTERIOR CRUCIATE LIGAMENT: A CASE REPORT

Krishna Amith Kumar, Ranjith Narayan

MBBS, MS Orthopaedics, Department of Orthopaedics, Aster Hospital Mankool, Dubai. UAE

✉ Krishna Amith Kumar, MD: dr_kamit@yahoo.com

✉ Ranjith Narayan, MD: ranjithort@gmail.com