

## ОРИГІНАЛЬНІ СТАТТІ

УДК 616-073.753:535-1]-058.835(045)

DOI: <http://dx.doi.org/10.15674/0030-5987202515-12>**Remote infrared thermography in the system of comprehensive diagnostics of the health of military personnel before surgical intervention****O. O. Kostrub<sup>1</sup>, O. I. Shukalo<sup>1</sup>, V. I. Dunaievskiy<sup>2</sup>,  
V. Y. Kotovskiy<sup>3</sup>, V. I. Timofeiev<sup>3</sup>, S. S. Nazarchuk<sup>3</sup>**<sup>1</sup> SI «Institute of Traumatology and Orthopedics of the National Academy of Medical Sciences of Ukraine», Kyiv<sup>2</sup> V. Ye. Lashkaryov Institute of Semiconductor Physics, National Academy of Sciences of Ukraine, Kyiv<sup>3</sup> National Technical University of Ukraine «Igor Sikorsky Kyiv Polytechnic Institute»

*A complete and informative diagnosis of the general health of military personnel before surgical intervention is of great importance for its successful implementation. A simple and affordable diagnostic method of radiological diagnostics is the method of remote infrared thermography. Conducting a comprehensive thermographic examination of military personnel before surgical intervention allows for the treatment of those pathological conditions that were detected during the thermographic examination. Objective. To show the possibility and evaluate the diagnostic informativeness remote infrared thermography in the system of comprehensive diagnostic monitoring of the health of military personnel before surgical intervention; to obtain thermographic visualizations of detected pathological changes associated with participation in combat operations. Methods. The work used a domestic thermograph with a temperature sensitivity of 0.07 °C and a ThermaCAM thermograph E 300 FLIR SYSTEM. Observation and control of thermal fields were carried out in the ranges of 3÷5 μm and 8÷14 μm. The examination was carried out during inpatient and outpatient treatment. Results. Received thermographic visualizations detected pathologies: disorders functions breathing; thermal asymmetries zones projections lung because of COVID-19; complications after firearm injury — pneumothorax; zones hyperthermia temporal bones due to contusion; vascular pattern disorders in the thyroid gland; functional and chronic disorders organs gastrointestinal and urological pathologies; degenerative-dystrophic musculoskeletal changes The oscillographic distributions of temperature patterns of the detected pathological conditions, which characterize the severity of traumatic and degenerative-dystrophic changes, were studied. Conclusions. In the presented work for the first time obtained and the results of a comprehensive thermographic health check-up military personnel after a long stay in the combat zone and before operational Remote infrared thermography, as one of the methods of radiological diagnostics, allows for a comprehensive examination of a significant number of military personnel in a short period of time and to identify pathological changes that require additional examination by narrowly specialized specialists.*

*Повноцінна й інформативна діагностика загального стану здоров'я військовослужбовців перед хірургічним втручанням має велике значення для його успішного проведення. Простим і доступним діагностичним методом променевої діагностики є спосіб дистанційної інфрачервоної термографії. Мета. Показати можливість та оцінити діагностичну інформативність дистанційної інфрачервоної термографії в системі комплексного діагностичного контролю за станом здоров'я військовослужбовців перед оперативним втручанням; отримати термографічні візуалізації виявлених патологічних змін, пов'язаних з участю в бойових діях. Методи. Застосовано вітчизняний термограф із температурною чутливістю 0,07 °C і термограф ThermaCAM E300 FLIR SYSTEM. Спостереження та контроль теплових полів здійснювались у діапазонах 3÷5 та 8÷14 мкм. Обстеження проводилось під час стаціонарного й амбулаторного лікування. Результати. Отримані термографічні візуалізації виявлених патологій: порушення функції дихання; термоасиметрії зони проєкції легень після перенесеного COVID-19; ускладнення після вогнепального поранення — пневмоторакс; зони гіпертермії скроневих кісток унаслідок контузії; порушення судинного рисунку в щитоподібній залозі; функціональні та хронічні розлади органів шлунково-кишкового тракту й урологічні патології; дегенеративно-дистрофічні зміни опорно-рухового апарата. Висновки. Наведено вперше отримані результати комплексного термографічного обстеження стану здоров'я військовослужбовців після тривалого перебування в зоні бойових дій та перед оперативним втручанням. Дистанційна інфрачервона термографія, як один із методів променевої діагностики, дозволяє комплексно обстежити значну кількість військових за короткий період часу та виявити патологічні зміни, які потребують додаткового обстеження вузькопрофільними спеціалістами. Ключові слова. Інфрачервона термографія, градієнт, температура, військовослужбовці, осцилографічний термозріз.*

**Keywords.** Infrared thermography, gradient, temperature, military personnel, oscillographic thermal image

## Introduction

Non-invasive research methods in clinical diagnostic medicine with the maximum informative content of examination results allows detecting diseases at an early stage, which is the key to successful treatment.

Such non-invasive diagnostic methods of modern radiology include computer thermal diagnostics, which is based on highly sensitive spectral fixation of infrared radiation of the affected anatomical structure with the possibility of further digital processing of the obtained information on thermal radiation of organs and tissues of the human body [1, 2].

To verify the diagnosis in the shortest possible time or determine the need for its verification using other clinical methods, as well as monitor the course of the disease over a long period of time and evaluate the effectiveness of the treatment process.

Modern thermal imaging systems use multi-element matrix photodetectors in the so-called «instantaneous look» mode. The formation of a thermal image is created by projecting the study area using a lens onto the matrix photodetector, electronically reading information from the photodetector matrix element by element, and presenting the thermograms on the PC display screen.

The thermograph provides the ability to perform measurements in any part of the skin surface (SS) of a biological object (BO) in the ranges of  $3\div 5\ \mu\text{m}$  and  $8\div 14\ \mu\text{m}$ . The ability to visualize the studied BO with qualitatively new characteristics (temperature sensitivity, image contrast) allows significantly expanding the scope of application of remote infrared thermography (RIT) in medical practice. Intensive work is underway to improve the software and hardware [3, 4].

The RIT method does not compete with other diagnostic methods. It occupies its own special niche as a diagnostic and preventive method, which is associated with analytical and radiological diagnostics. RIT contributes to reducing the duration of primary diagnostics, predicting treatment tactics and timely establishing the necessary nature and volume of medical care.

It should be noted that temperature is a universal reflection of the vital activity of the body. A change in temperature distribution is a potential signal of the development of a pathological process, which can manifest itself in one of three thermographic signs: the existence of anomalous zones of hypo- or hyperthermia, a violation of the normal thermotopographic pattern, as well as a change in the tempera-

ture gradient in the area under study. Inflammatory processes cause a change in the gradient between the affected area and surrounding tissues: in chronic inflammatory processes  $0.7\ ^\circ\text{C}$ , in acute  $1.0\text{--}1.5\ ^\circ\text{C}$ , in purulent-destructive  $1.5\text{--}2.0\ ^\circ\text{C}$ . Analysis of thermograms includes their qualitative and quantitative assessment. Qualitative assessment is the visualization of the thermal picture on the surface of the BO (distribution of «hot» and «cold» areas). The quantitative assessment includes the so-called temperature gradient — the difference between the temperature of the studied area and the neighboring area, which makes it possible to take into account the localization of the exposed area, the degree of its vascularization and the severity of the pathological process. In addition to changes in the temperature gradient, thermograms during inflammatory processes register zones of thermal asymmetry, which in shape, size and location correspond to the most pathological changes.

The presence of pathological changes in internal organs leads to temperature anomalies and is projected onto the skin due to tissue thermal conductivity, capillary convection, and convection through large vessels. In addition, local changes in tissue temperature often appear before structural changes that can be detected by other instrumental methods.

Thus, thermography makes it possible to identify the relationship between the severity of clinical manifestations of a potential disease and the temperature of the respiratory tract.

In conditions of military operations, it is impossible to ensure the conduct of high-quality diagnostic measures to determine the health status of military personnel, especially those who have been wounded and injured. RIT is a mobile diagnostic complex that allows you to obtain information about damaged areas and the scope of surgical intervention.

To diagnose the health of military personnel, complex laboratory and instrumental diagnostic methods are used, such as: radiography (RF); computed tomography (CT); ultrasound diagnostics (USD); magnetic resonance imaging (MRI) and others.

Each of the above diagnostic methods has its own advantages and disadvantages. Significant radiation exposure to the subject, which requires a certain period of time before the next examination, significant cost and insufficient informativeness, especially in the early stages of the development of the pathological process, necessitated the use of the RIT method.

The current level of development of thermal imaging technology allows for the reliable diagnosis of a wide range of diseases, which is reflected in the works of domestic and foreign clinicians [2, 5–11].

The undeniable advantages of this method in medicine are: remote and non-invasive nature of the study, the possibility of repeated use both during comprehensive diagnostic examinations and during treatment for the purpose of monitoring and correcting therapeutic measures.

*Objective:* to perform a comprehensive examination of the health of military personnel using the method of remote infrared thermography before surgical intervention; to obtain thermograms of pathological changes associated with participation in combat operations; to analyze oscillographic temperature patterns of the thermal field.

## Material and methods

The work used a domestic thermograph with a temperature sensitivity of 0.07 °C developed by the V. Ye. Lashkaryov Institute of Semiconductor Physics of the NAS of Ukraine with a cooled matrix photodetector and a basic test program for the TherrmoVisio thermal imaging system, as well as the ThermaCAM E300 FLIR SYSTEM thermograph. Observation and control of thermal fields was carried out in the ranges of 3÷5 μm and 8÷14 μm. The implementation of program codes was carried out in the Delphi programming language in the Borland Delphi 7 development environment.

When formatting the results of thermographic studies (personal thermographic patient card), the program uses the properties of a Microsoft Word document to create a template and inserts them into the appropriate field of the text editor, and also adds a set of special commands necessary for working with infrared (IR) images (the ability to insert a text comment, a patient photo card, his IR image, the required thermal profile, a results table, etc.) and various research tools. The diagnostic information obtained in this way can be stored as an electronic card in the Basic IR Photo template for further operational analysis, observation and prediction of the dynamics of the functional state.

The examination was conducted during inpatient and outpatient treatment. The age of the patients ranged from 25 to 58 years, the weight of the patients ranged from 55 kg to 80 kg depending on age, the number of examined persons was 66. No special division of patients into groups was carried out.

Before the thermographic examination, the patients did not undergo thermal procedures, they did not take medications that affect blood circulation and metabolic processes, and they were also subject to adaptation to the temperature conditions of the thermography room.

The study was conducted in accordance with the principles of bioethics set forth in the Declaration of Helsinki «Ethical Principles for Medical Research Involving Human Subjects» and the «Universal Declaration on Bioethics and Human Rights» (UNESCO).

Thermogram processing and further actions to format the results of thermographic studies were performed using the TherrmoVisio program, which was improved by the authors and allows obtaining thermographic images with removed background noise and imperfect pixels, and simplifying the obtaining of oscillographic thermal sections in the real temperature value [12, 13].

## Results

The paper presents the results of a comprehensive thermographic examination of military personnel before surgical intervention on knee joints, which they received in the combat zone.

Being in difficult field conditions and not being able to contact medical specialists in a timely manner regarding diseases, military personnel experience exacerbation of both chronic and acquired pathologies. The combination of gunshot wounds with other types of diseases such as: traumatic injuries of the musculoskeletal system, inflammatory processes of the ENT organs and respiratory organs, frostbite and hypothermia in winter require multidisciplinary diagnostic methods. The RIT method allows you to effectively get an idea of the prevalence and nature of diseases with the possibility of photofixation and ensuring dynamic monitoring of pathological processes.

The inflammatory process in the maxillary and frontal cavities, which leads to impaired respiratory function, is the most common pathological condition. One of the causes of this pathology is a congenital or acquired deviation of the nasal septum.

Fig. 1, a shows thermographic visualization — impaired respiratory function on the left (the air flow inhaled through the right nasal cavity is isolated, through the left — absent). The pathological condition revealed is a deviation of the nasal septum and an inflammatory process in the maxillary sinuses. The temperature gradient on the left is:  $\Delta T \text{ } ^\circ\text{C} = +1.42 \text{ } ^\circ\text{C}$ , on the right —  $+0.83 \text{ } ^\circ\text{C}$ .

The thyroid gland (TH) has significant vascularization and is located directly under the thyroid gland, making it an easily accessible organ for thermographic examination [11]. Thermographic visualization of pathological changes and oscillographic temperature distribution in the projection zone of the thyroid gland on the right are shown in

Fig. 1, b, c. The hyperthermic area is characterized by a temperature gradient of  $+1.48\text{ }^{\circ}\text{C}$ , which is a diagnostic signal for a detailed examination of the thyroid gland.

A thermographic examination of a serviceman was performed during the rehabilitation period after a gunshot wound to the left lung and a complication — left-sided pneumothorax (shown by arrow 1, Fig. 1, d). The temperature gradient between the selected and adjacent areas (arrows 1 and 2, respectively) is:  $\Delta T^{\circ}1-2 = +1.52\text{ }^{\circ}\text{C}$ , which indicates the presence of pathological changes in the lungs.

Thermography, as part of the differential diagnosis of diseases of the bronchopulmonary system, allows you to identify areas of local hyperthermia and thermal asymmetry of the posterior projection of the lungs [14, 15].

It should be noted that thermographic imaging of lung thermal fields in patients after COVID-19 differs from thermographic imaging of the lungs after bacterial or viral pneumonia not associated with COVID-19.

Fig. 1, e, f shows a thermogram of the posterior projection of the lungs (history of COVID-19) and an oscillographic thermal section relative to the line. The temperature gradient in the projection zone of the left lung is  $+1.74\text{ }^{\circ}\text{C}$ ; in the right lung zone —  $+1.87\text{ }^{\circ}\text{C}$ .

One of the characteristic signs of COVID-associated pneumonia is the symptom of “ground glass” — areas of reduced transparency of the lung parenchyma, which have a low density, against the background of “ground glass” vessels and bronchi are differentiated, which are distinguished by a denser structure [15, 16]. Parenchymal consolidation (consolidation) is an area of often irregular shape, which exceeds the density of the “ground glass” zone, due to which vessels and bronchi are not visualized. Consolidation is also due to the accumulation of exudate in the alveolar spaces, which is characteristic of bacterial pneumonia, which affects the nature of infrared radiation from lung tissue.

A dangerous health condition is contusion [17], which is thermographically visualized as hyperthermia of the temporal part (Fig. 2, a, c). The temperature gradient in the hyperthermia zone on the left (arrow 1) has a maximum value of  $+3.03\text{ }^{\circ}\text{C}$  and  $+2.96\text{ }^{\circ}\text{C}$  (arrow 3 — intact zone). The serviceman received a bullet wound in the area shown by arrow 2 in Fig. 2, a. The temperature distribution oscillogram (b) is made relative to the line ((a), bullet wound zone), on which the appearance of separate zones with temperature maxima is observed (zones 1,

2 are highlighted in Fig. 2, b). After the temperature drop, we observe a sharply pronounced zone (3) with a maximum temperature corresponding to the area of the bullet wound; the thermogram of the temporal part on the right with the oscillographic temperature distribution (c, d — respectively) is also shown.

Gastrointestinal disorders (GI) appear as various combinations of chronic or recurrent symptoms, which often indicate the result of the interaction of psychosocial factors and changes in the physiology of the stomach, gallbladder, intestine in field conditions. The appearance of pathological changes in the organs of the digestive system leads to changes in the temperature indicators of the abdominal cavity.

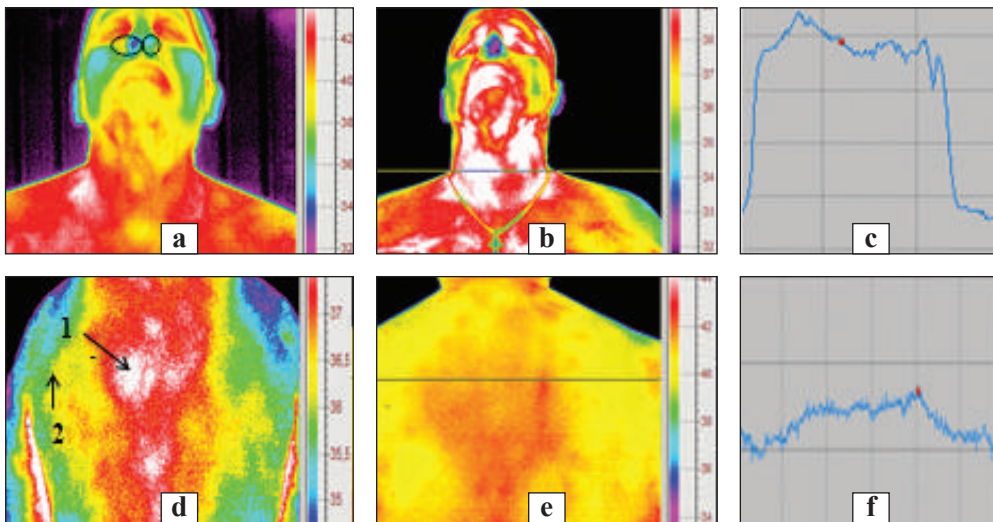
Fig. 3, a shows the projection zone of the pancreas, performed by the ThermaCAM E300 FLIR SYSTEM thermograph. Temperature fluctuations in the visualization zone of the pancreas (along the line in Fig. 3, a) are in the range from  $32.7\text{ }^{\circ}\text{C}$  to  $34.2\text{ }^{\circ}\text{C}$ .

The use of the RIT method for detecting urological pathology complements the comprehensive diagnostic base. As an example, Fig. 3, b shows thermographic visualization of hypothermia areas in the kidney projection zone. This nature of thermographic visualization indicates the presence of urolithiasis, which is confirmed in the anamnesis. The temperature gradient of the left kidney projection zone is: —  $1.3\text{ }^{\circ}\text{C}$ , on the right: —  $1.8\text{ }^{\circ}\text{C}$ .

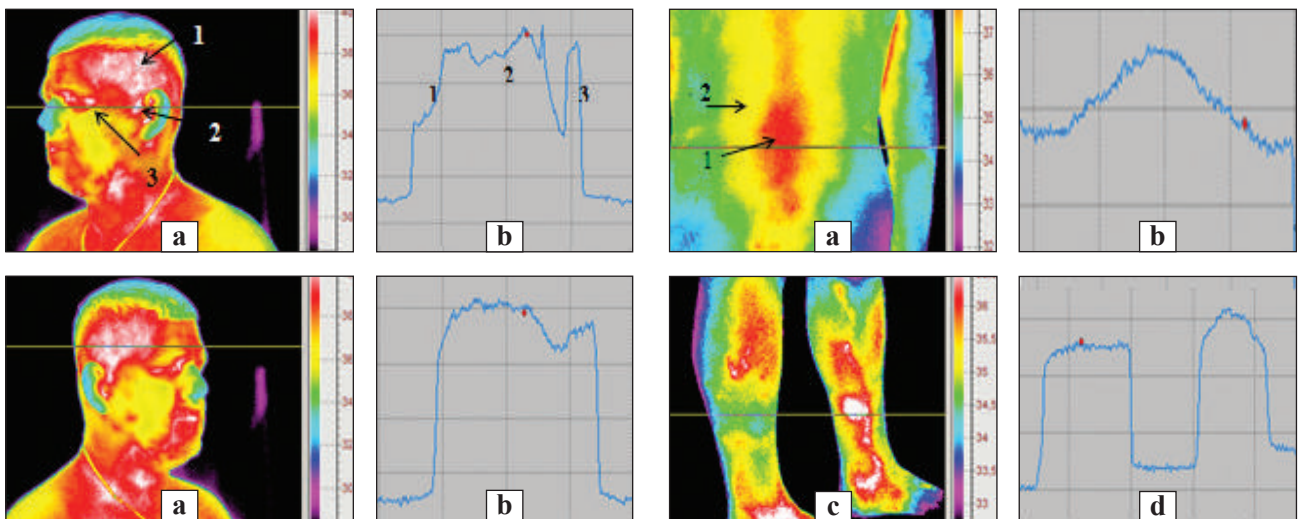
Significant physical exertion leads to exacerbation of degenerative-dystrophic changes, discogenic pathologies of the spine in military personnel. RIT provides an opportunity to promptly and objectively assess the severity of the identified pathologies. Thus, in Fig. 4, a, a hyperthermia area in the lumbosacral region is presented (arrow 1, a; arrow 2 — intact zone) and oscillographic distribution (b) relative to the line; the temperature gradient is:  $\Delta T\ 2-1 = +1.87\text{ }^{\circ}\text{C}$ , which indicates an exacerbation of the identified pathology and significant pain syndrome.

The presented thermogram (Fig. 4, c) and oscillographic temperature distribution (Fig. 4, d) visualize Thermotopography of the lower limb with temperature changes characteristic of a vascular disorder — varicose veins (VV). VV of the left lower limb is represented by uneven saccular dilation of the veins, accompanied by valve insufficiency and impaired blood flow.

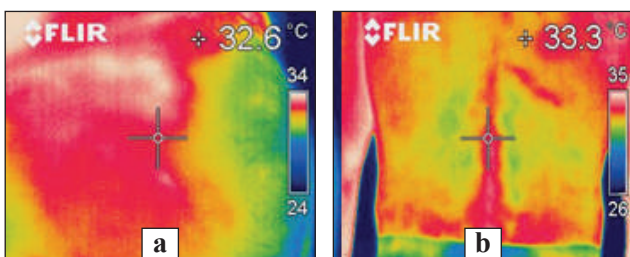
The presence of VVD imposes restrictions on the ability to perform heavy physical exertion. According to the authors, circulatory disorders serve as a prerequisite for the occurrence of functional and degenerative changes in the knee joints, which was also reflected in the works of other researchers [18–21].



**Fig. 1.** Impaired respiratory function on the left (a); hyperthermia of the right lobe of the thyroid gland (b) and temperature distribution oscillogram relative to the line (c); hyperthermia of the posterior projection of the lungs, pneumothorax (d); hyperthermia of the posterior projection of the lungs after COVID-19 (e) and temperature distribution oscillogram (f) relative to the line

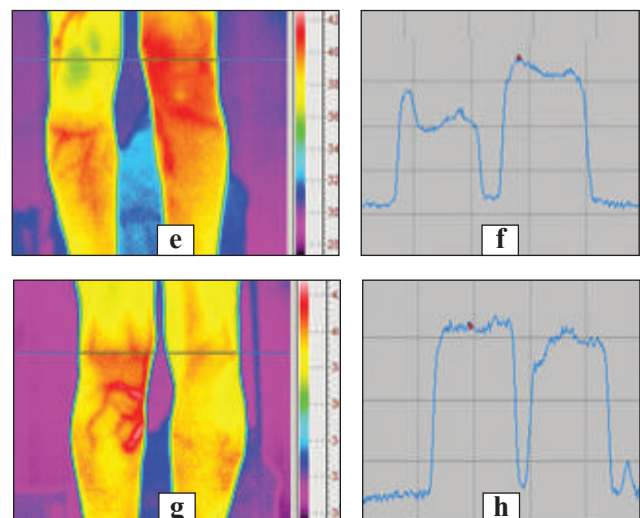


**Fig. 2.** Hyperthermia of the temporal regions (a, c) due to concussion, (arrow 2 – site of bullet wound); oscillographic distribution of temperature (b, d) relative to the lines



**Fig. 3.** Hyperthermia of the projection zone of the pancreas (a); hypothermia of the projection zone of the kidneys (b)

Orthopedic pathology of the knee joints occupies a leading position in terms of frequency of occurrence among degenerative-dystrophic diseases of the musculoskeletal system in military personnel. An important aspect of the problem is the timely diagnosis of the disease using simple and affordable methods of radiological diagnostics.



**Fig. 4.** Hyperthermia of the lumbosacral region (a) and oscillographic distribution (b) relative to the line; HRV of the lower extremities (c) and oscillographic distribution (d) relative to the line; hyperthermia of the left knee joint after anterior cruciate ligament reconstruction, partial resection of the medial meniscus: anterior (e) and posterior (g) projections; oscillographic distribution (f, h) relative to the lines

Thermographic visualization of knee joints with various manifestations of lesions allows you to reliably and informatively enrich the comprehensive diagnostics of the musculoskeletal system, provide an assessment of the effectiveness of treatment and safely monitor it [12, 22–24].

Fig. 4, e, shows thermographic visualization of the left knee joint after surgical treatment — anterior cruciate ligament reconstruction, partial resection of the medial meniscus. The condition after surgery and the presence of implants leads to changes in temperature patterns, presented in oscillographic temperature distributions (Fig. 4, e, g).

## Discussion

In connection with military operations, interest in the use of RIT, which is aimed at identifying and timely treating diseases in military personnel, has significantly increased.

The authors of the work [25–26] investigated the diagnostic capabilities of spectral infrared thermography in the treatment of gunshot wounds of soft tissues. The issue of the use of RIT in obliterating diseases of the lower extremities is the subject of the work of the author [18]. The use of the thermal imaging control technique for monitoring the dynamics of thermal fields on the SS in the case of short-term cryosurgical treatment of soft tissue pathology with quasi-point the authors' work [27] is devoted to the cryoapplicator. The feasibility of using thermal imaging studies in medicine to obtain thermal radiation from the CB's SS is described in [3]. Visualized thermal radiation makes it possible to assess the state of both peripheral blood circulation and obtain information about deep processes in the body.

The authors of [28] used the thermographic method to assess the condition of military personnel before and after surgical intervention due to gunshot wounds, which allows for timely detection of complications and taking prompt medical measures to prevent postoperative complications.

In the presented work, the results of a comprehensive thermographic examination of the health status of military personnel before surgical intervention are obtained for the first time. Oscillographic distributions of temperature patterns of detected pathological conditions are presented separately, which characterize the severity of traumatic and degenerative-dystrophic changes. Thermographic visualizations of detected pathologies were obtained: respiratory function disorders; hyperthermia of the lung projection zone after COVID-19 and complications due to gunshot wound — pneumothorax; hyper-

thermia of the temporal parts after contusion; pathological processes in the thyroid gland; functional and chronic disorders of the gastrointestinal tract and urological pathologies; degenerative-dystrophic changes in the musculoskeletal system. A comprehensive understanding of the health status of military personnel will be the key to successful surgical intervention and will contribute to a speedy recovery.

## Conclusions

Preservation of the health of military personnel is a top priority for ensuring the combat readiness of military units. The use of existing radiation diagnostic methods in field conditions and in conditions of front-line deployment of military personnel is a problematic issue due to the use of complex equipment and limited capabilities for conducting diagnostic actions.

First performed comprehensive thermographic examination of military personnel before surgical intervention: obtained thermographic visualizations and oscillographic temperature distributions of such pathological conditions as contusion, bullet wound, residual phenomena in the bronchopulmonary system due to COVID-19, exacerbation of chronic diseases of the pancreas and urinary system, traumatic injuries of the musculoskeletal system, etc.

Remote infrared thermography, as one of the methods of radiation diagnostics, in the system of comprehensive diagnostic measures additionally provides doctors of almost all specialties with important information about the presence and severity of detected pathologies before surgical intervention.

Given the ease of use, mobility, significant informativeness and efficiency, it is advisable to introduce the method of remote infrared thermography into the system of comprehensive diagnostic measures at various stages of providing medical care to military personnel.

**Conflict of interest.** The authors declare no conflict of interest.

**Prospects for further research.** Prospects for further research include the use of the remote infrared thermography method in the postoperative period to determine the course of wound regeneration, as well as monitoring the health of servicemen after identified pathological conditions during thermographic examination and appropriate treatment. Special attention will be paid to the study of the state of health of servicemen after mine-explosive injuries, complications after diseases of the bronchopulmonary system, neuropathy. Actual and promising work on expanding the information base of thermographic visualizations of identified pathological conditions, which can be used by doctors of almost all specialties in medical practice.

**Funding information.** The authors declare the absence of their own financial interest in the preparation of this article.

**Author's contribution.** Each of the authors took an equal part in determining the topic of the article, in selecting patients,

conducting thermographic examinations, analyzing and discussing the results of the work, processing literary sources and preparing the obtained materials for publication.

## References

- Ostafiychuk, D. I., Shaiko-Shaikovsky, O. S., Bilov, M. E., & Chibotaru, K. I. (2019). Thermography, application in medicine. *Clinical & Experimental Pathology*, 18 (1). <https://doi.org/10.24061/1727-4338.xviii.1.68.2019.21>
- Keszytüs, D., Brucher, S., Wilson, C., & Keszytüs, T. (2023). Use of infrared thermography in medical diagnosis, screening, and disease monitoring: A scoping review. *Medicina*, 59 (12), 2139. <https://doi.org/10.3390/medicina59122139>
- Oliynyk, G. A. (2018). Thermal radiation and thermal imaging research in medicine. *Ukrainian medical dental academy*, 18 (2 (62)), Article [http://nbuv.gov.ua/UJRN/apsm\\_2018\\_18\\_2\\_61](http://nbuv.gov.ua/UJRN/apsm_2018_18_2_61).
- Requena-Bueno, L., Priego-Quesada, J. I., Jimenez-Perez, I., Gil-Calvo, M., & Pérez-Soriano, P. (2020). Validation of ThermoHuman automatic thermographic software for assessing foot temperature before and after running. *Journal of Thermal Biology*, 92, 102639. <https://doi.org/10.1016/j.jtherbio.2020.102639>
- Ramirez-GarcíaLuna, J. L., Bartlett, R., Arriaga-Caballero, J. E., Fraser, R. DJ, & Saiko, G. (2022). Infrared thermography in wound care, surgery, and sports medicine: A review. *Frontiers in Physiology*, 13. <https://doi.org/10.3389/fphys.2022.838528>
- Kolacz, S., Moderhak, M., & Jankau, J. (2017). New perspective on the in vivo use of cold stress dynamic thermography in integumental reconstruction with the use of skin-muscle flaps. *Journal of Surgical Research*, 212, 68–76. <https://doi.org/10.1016/j.jss.2016.12.022>
- Glik, J., Cholewka, A., Stanek, A., Englisz, B., Sieroń, K., Mikuś-Zagórska, K., Knefel, G., Nowak, M., Kawecki, M. (2019). Thermal imaging and planimetry evaluation of the results of chronic wounds treatment with hyperbaric oxygen therapy. *Adv Clin Exp Med*, 28(2), 229–236. <https://doi.org/10.17219/acem/92304>. PMID: 30238703.
- Stoyanovsky, I. V., Khimich, S. D., Chemerys, O. M. (2024). Effectiveness using infrared thermography for diagnostics necrotizing fasciitis. *Surgery children's century*, (3(84)), 38–43. [https://doi.org/10.15574/PS.2024.3\(84\).3843](https://doi.org/10.15574/PS.2024.3(84).3843)
- Carrière, M. E., Haas, L. EM, Pijpe, A., Meij-de Vries, A., Gardien, K. LM, Zuijlen, P. PM, & Jaspers, M. EH (2019). Validity of thermography for measuring burn wound healing potential. *Wound Repair and Regeneration*, 28(3), 347–354. <https://doi.org/10.1111/wrr.12786>
- Sillero-Quintana, M., Fernández-Jaén, T., Fernández-Cuevas, I., Gómez-Carmona, PM, Arnaiz-Lastras, J., Pérez, M.-D., Guillén, P. (2015). Infrared thermography as a support tool for screening and early diagnosis in emergencies. *J. Med. Imaging Health Inform.*, (5), 1223–1228. <https://doi.org/10.4018/978-1-5225-2072-6.ch008>
- Damião, C. P., Montero, J. RG, Moran, M. BH, de Oliveira Marçal e Silva Carvalho, M. E., de Farias, C. G., Brito, I. B., Saad, M. AN, Fontes, C. AP, Fainstein, C., Rodrigues, M. FO, Palombo, A., Conci, A., da Cruz Filho, R. A., & Lima, G. AB. (2021). Application of thermography in the diagnostic investigation of thyroid nodules. *Endocrine Journal*, 68 (5), 573–581. <https://doi.org/10.1507/endocrj.ej20-0541>
- Poliachenko, Y. V., Blonskyi, R. I., Kostrub, O. O., Dunaievskiy, V. I., Kotovskyi, V. Y., & Timofeiev, V. I. (2024). Research of the temperature patterns distribution of pathological conditions of the knee joints. *World of Medicine and Biology*, 20 (89), 142. <https://doi.org/10.26724/2079-8334-2024-3-89-142-148>
- Dunaievsky, V., Kotovskyi, V., Nazarchuk, S., Kyslyi, V. (2021). Expanding the modern approaches of diagnostics of the state of a biological object by introducing infrared thermography. National Health as Determinant of Sustainable Development of Society: Monograph / Ed. By N. Dubrovina, St. Filip. Bratislava, 35–55. [https://dspace.uzhnu.edu.ua/jspui/bitstream/lib/37505/3/Mono\\_VSEMvsMED2021.pdf](https://dspace.uzhnu.edu.ua/jspui/bitstream/lib/37505/3/Mono_VSEMvsMED2021.pdf)
- Grechanik, O. I., Abdullaiev, R. R., Nikonov, V. V., Voronzhnev, I. O., Abdullaiev, R. Y., & Davidy, M. M. (2024). Radiologic diagnosis of pneumothorax in combat trauma. *Emergency Medicine*, 20 (3), 203–210. <https://doi.org/10.22141/2224-0586.20.3.2024.1693>
- Brzezinski, R. Y., Rabin, N., Lewis, N., Peled, R., Kerpel, A., Tsur, A. M., Gendelman, O., Naftali-Shani, N., Gringauz, I., Amital, H., Leibowitz, A., Mayan, H., Ben-Zvi, I., Heller, E., Shechtman, L., Rogowski, O., Shenhar-Tsarfaty, S., Konen, E., Marom, E.M., ... Hoffer, O. (2021). Automated processing of thermal imaging to detect COVID-19. *Scientific Reports*, 11 (1). <https://doi.org/10.1038/s41598-021-96900-9>
- Feshchenko, Y. (2021). Features damage lungs in COVID-19. *Ukr. Pulmonol. Journal*, (1), 5–14. <https://doi.org/10.31215/2306-4927-2021-29-1-5-14>
- Cai, F., Jiang, X., Hou, X., Wang, D., Wang, Y., Deng, H., Guo, H., Wang, H., & Li, X. (2020). Application of infrared thermography in early warning of pressure injury: A prospective observational study. *Journal of Clinical Nursing*. <https://doi.org/10.1111/jocn.15576>
- Krysa, B. V., Krysa, V. V. (2024). Distance thermography for obliterating diseases lower limbs *Proceedings of the International Scientific and Practical Conference "Diversity and Inclusion in Scientific Area"*, (March 26-28, 2024, Warsaw, Poland.), 348–356.
- Menegatti, E., Mandini, S., Pagani, A., Mandini, B., Zerbini, V., Piva, T., Raisi, A., Fabbri, M., Fogli, M., Mazzoni, G., Zamboni, P., & Gianesini, S. (2022). The effect of active stretching training in patients with chronic venous insufficiency monitored by raster-stereography. *Sensors*, 22 (21), 8509. <https://doi.org/10.3390/s22218509> PMID: 36366206; PMCID: PMC9657419.
- Deng, F., Tang, Q., Zeng, G., Wu, H., Zhang, N., & Zhong, N. (2015). Effectiveness of digital infrared thermal imaging in detecting lower extremity deep venous thrombosis. *Medical Physics*, 42 (5), 2242–2248. <https://doi.org/10.1118/1.4907969>
- Ilo, A., Romsis, P., & Mäkelä, J. (2020). Infrared thermography as a diagnostic tool for peripheral artery disease. *Advances in Skin & Wound Care*, 33 (9), 482–488. <https://doi.org/10.1097/01.asw.0000694156.62834.8b>
- De Marziani L, Boffa A, Angelelli L, Andriolo L, Di Martino A, Zaffagnini S, Filardo G. (2023). Infrared thermography in symptomatic knee osteoarthritis: Joint temperature differs based on patient and pain characteristics. *J Clin Med.*, (12(6)), 2319. PMID: 36983319; PMCID: PMC10055129.
- Jones, B., Hassan, I., Tsuyuki, R. T., Dos Santos, M. F., Russell, A. S., & Yacyshyn, E. (2018). Hot joints: Myth or reality? A thermographic joint assessment of inflammatory arthritis patients. *Clinical Rheumatology*, 37 (9), 2567–2571. <https://doi.org/10.1007/s10067-018-4108-0>
- Windisch, C., Brodt, S., Roehner, E., & Matziolis, G. (2015). Regional differences in temperature course after knee arthroplasty. *Knee Surgery, Sports Traumatology, Arthroscopy*, 24 (8), 2686–2691. <https://doi.org/10.1007/s00167-015-3809-z>
- Khomenko, I. P., Tsema, E. V., Shapovalov, V. Yu., Tertyshny, S. V., Grinchuk, M. M. (2018). Diagnostic opportunities spectral infrared thermography in treatment firearms injuries soft tissue. *Integrative Anthropology*, (2(32)), 43–47. [http://nbuv.gov.ua/UJRN/ia\\_2018\\_2\\_10](http://nbuv.gov.ua/UJRN/ia_2018_2_10)
- Khomenko, I., Tsema, Y., Gumenuk, K., Tertyshnyi, S. (2020). Creation Concept of The rmographic Classification of Gunshot Wounds of Soft Tissues. *World Science*, 1 (4(56)), 32–36.

- [https://doi.org/10.31435/rsglobal\\_ws/30042020/7022](https://doi.org/10.31435/rsglobal_ws/30042020/7022)
27. Chyzh, M. O., Kovalov, H. O., Shustakova, H. V., Fomenko, Y. V., & Gordiyenko, E. Y. (2023). The procedure of thermal imaging control of the temperature fields on the skin during cryoablation. *The Odessa Medical Journal*, (4), 88–93. <https://doi.org/10.32782/2226-2008-2023-4-17>
28. Khoroshun, E. M., Makarov, V. V., Nehoduiko, V. V., Shipilov, S. A., Klapchuk, Y. V., & Tertyshnyi, S. V. (2023). Problems of diagnosis and treatment of tourniquet syndrome in gunshot wounds of the upper and lower extremities. *Paediatrics Surgery. Ukraine*, (3(80)), 83–91. <https://doi.org/10.15574/ps.2023.80.83>

Стаття надійшла до редакції 29.01.2025	Отримано після рецензування 25.02.2025	Прийнято до друку 27.02.2025
---	---	---------------------------------

## ДИСТАНЦІЙНА ІНФРАЧЕРВОНА ТЕРМОГРАФІЯ В СИСТЕМІ КОМПЛЕКСНОЇ ДІАГНОСТИКИ СТАНУ ЗДОРОВ'Я ВІЙСЬКОВОСЛУЖБОВЦІВ ПЕРЕД ОПЕРАТИВНИМ ВТРУЧАННЯМ

О. О. Коструб<sup>1</sup>, О. І. Шукало<sup>1</sup>, В. І. Дунаєвський<sup>2</sup>, В. І. Котовський<sup>3</sup>, В. І. Тимофеев<sup>3</sup>, С. С. Назарчук<sup>3</sup>

<sup>1</sup> ДУ «Інститут травматології та ортопедії НАМН України», Київ

<sup>2</sup> Інститут фізики напівпровідників ім. В. Є. Лашкарьова НАН України, Київ

<sup>3</sup> Національний технічний університет України «Київський політехнічний інститут імені Ігоря Сікорського»

✉ Oleksandr Kostруб, MD, DMSci, Prof.: [akostrub@ukr.net](mailto:akostrub@ukr.net); <https://orcid.org/0000-0001-7925-9362>

✉ Oleksandr Shukalo: [shukalooleksandr@gmail.com](mailto:shukalooleksandr@gmail.com)

✉ Vadim Dunaevsky, PhD: [dunayevskani@ukr.net](mailto:dunayevskani@ukr.net); <https://orcid.org/0000-0002-2106-9520>

✉ Vitaliy Kotovsky, DSci, Prof.: [kotovsk@kpi.ua](mailto:kotovsk@kpi.ua); <https://orcid.org/0000-0003-3372-7815>

✉ Volodymyr Tymofeev, DSci, Prof.: [v.timofeev@kpi.ua](mailto:v.timofeev@kpi.ua); <https://orcid.org/0000-0003-0515-1580>

✉ Svitlana Nazarchuk: [nazarchuksvet@gmail.com](mailto:nazarchuksvet@gmail.com); <https://orcid.org/0000-0002-3794-609X>