

КРАТКИЕ СООБЩЕНИЯ И ЗАМЕТКИ ИЗ ПРАКТИКИ

УДК 616.718.19-006.33-036.87:[616-005.7:678.744.7](045)

DOI: <http://dx.doi.org/10.15674/0030-59872019475-80>

Palliative embolization arteries or veins for a recurrent pelvic chondrosarcoma

C. Biz¹, A. Angelini¹, A. Crimi¹, G. Trovarelli¹,
V. G. Igoumenou², A. F. Mavrogenis², P. Ruggieri¹

¹ Department of Orthopaedics and Orthopaedic Oncology, University of Padova. Italy

² First Department of Orthopaedics, National and Kapodistrian University of Athens. Greece

Chondrosarcoma is a malignant bone tumor characterized by the formation of cartilage structures of varying degrees of maturity. They account for approximately 20 % of malignant skeletal tumors. Chondrosarcoma most often affects the pelvis (iliac bone), the proximal femur and humerus, ribs. The chondrosarcoma of the pelvis has a low response to chemo- and radiation therapy, so they are usually resected by standard hemipelvectomy. New surgical reconstructive techniques allow surgeons to perform major reconstructions, thereby improving patients' quality of life. Clinical case: male, 64 years old, with complains of the left thigh pain for 6 months. The patient was made a comprehensive examination — standard X-rays, MRI and CT scan of the pelvis, biopsy of the pathological formation. Diagnosis: chondrosarcoma II clinical group, stage IIB. Primary surgery — wide-field excision and reconstruction with a massive bone allograft was performed and bipolar hip replacement. Two major local recurrences were detected in 3 years. Due to inefficiency of chemo- and radiation therapy, refusal of the patient from amputation, high degree of tumor vascularization, arterial embolization was applied. A selective study of both the medial and lateral femoral arteries was performed using a uroangiographic contrast medium. The achievement of complete devascularization of the greatest lesion was confirmed angiographically. After 20 days due to partial revascularization, re-embolization of the lateral circular femoral artery was made. The final embolization of all arterial branches that fed the tumor was performed after 3 months with acrylic (n-butyl 2-cyanoacrylate) glue for larger-sized vessels and microparticles of polyvinyl alcohol (150–250 μm) for the smallest branches. Conclusion: embolization can be effectively used as a palliative treatment for highly vascularized pelvic chondrosarcoma. Key words: chondrosarcoma, pelvis, embolization, palliative, polyvinyl alcohol microparticles.

Хондросаркома (ХС) — це злоякісна пухлина кісток, характерною рисою якої є утворення хрящових структур різного ступеня зрілості. На них припадає приблизно 20 % злоякісних пухлин скелета. Найчастіше ХС вражає таз (клубову кістку), проксимальний відділ стегнової та плечової кісток, ребра. ХС малого таза мають низьку реакцію на хіміо- та променеви терапії, отже, зазвичай, їх резектують за допомогою стандартної геміпельвектомії. Нові хірургічні реконструктивні методи дозволяють хірургам проводити великі реконструкції, покращуючи тим самим якість життя пацієнтів. Клінічний випадок: чоловік, 64 роки, зі скаргами на болі в лівому стегні протягом 6 міс. Пацієнту виконано комплексне обстеження — стандартну рентгенографію, МРТ та КТ малого таза, біопсію патологічного утворення. Встановлено діагноз: ХС II клінічної групи, ІІВ стадії. Первинне хірургічне втручання — висічення з широкими полями та реконструкція масивним кістковим алотрансплантатом, встановлення біполярного ендопротеза стегна. Через 3 роки виявлено два великі локальні рецидиви. Через неефективність хіміо- та променевої терапій, відмову пацієнта від ампутації, високий ступінь васкуляризації пухлини виконано артеріальну емболізацію. Проведено селективне дослідження як медіальної, так і бічної стегнових артерій за допомогою уроангіографічного контрастного середовища. Досягнення повної деваскуляризації найбільшого ураження підтверджено ангіографічно. Через 20 днів у наслідок часткової реваскуляризації виконано повторну емболізацію бічної циркулярної стегнової артерії. Остаточну емболізацію всіх артеріальних гілок, які живлять пухлину, провели через 3 міс. за допомогою акрилового (н-бутил-2-ціаноакрилатного) клею для судин більшого діаметра та мікрочастинок полівінілового спирту (150–250 мкм) для найменших гілок. Висновок: емболізацію можна ефективно використовувати як паліативне лікування високоваскуляризованих ХС таза. Ключові слова: хондросаркома, таз, емболізація, паліативне лікування, мікрочастинки полівінілового спирту.

Key words: chondrosarcoma, pelvis, embolization, palliative, polyvinyl alcohol microparticles

Introduction

Chondrosarcomas are malignant bone tumors with pure hyaline cartilage differentiation, and behavior patterns that vary, ranging from slow-growing non-metastasizing lesions to aggressive metastasizing sarcomas [1]. They account for approximately 20 % of malignant bone tumors, belonging among the most common primary bone malignancies [2]. The most common location is the pelvis, most commonly the ilium, followed by the proximal femur, proximal humerus, distal femur and ribs [2].

Pelvic chondrosarcomas have a low response to chemotherapy and radiotherapy [3, 4], therefore, they have been usually en-bloc resected by standard hemipelvectomy [5]. Novel surgical reconstructive techniques permit surgeons to perform extensive reconstructions, thus improving the quality of life of affected patients; reconstructive procedures include vascularized and non-vascularized autologous bone grafts, massive allografts, autoclaved allografts and hemipelvic prostheses (modular, composite or custom-made) [2, 6, 7]. However, the risk of local recurrence remains high, and sometimes a subsequent amputation is required [3, 8, 9]. Few studies have focused on palliative treatments for recurrent chondrosarcomas and, to the best of our knowledge, there is no evidence of a similar case reported in the English literature.

We hereby present the case of a patient with recurrent chondrosarcoma involving the pelvis, treated with palliative serial selective arterial embolizations, aiming to obtain good clinical results with regard to pain control, ambulation and time of survival.

Case Report

A 64-year-old man was referred to the authors' institution due to a 6-month history of progressive left hip pain and worsening ambulation. The patient

had no specific history of trauma. Apart from mild hypertension and hypercholesterolemia, no other significant pathologies were present. The physical examination revealed a voluminous painful hard mass involving the hip and the groin area. The overlying skin was hot, red and swollen. No ulcers or fistulas were present, and the neurovascular apparatus was intact. Performance status was 80 %, according to Karnofsky scale, and physical status was ASA 2. After complete staging with standard X-ray, MRI and CT scan of the pelvis, a solid mass was observed with well-defined sinuous margins, a transverse diameter of 5.7 cm and cranio-caudal diameter of 9 cm, involving the acetabular area (fig. 1); biopsy confirmed a diagnosis of grade 2 chondrosarcoma, stage IIB. The patient was therefore treated elsewhere by surgical excision with wide margins and reconstruction with a massive bone allograft and bi-articular hip prosthesis. Two months after surgery, the patient was surgically treated for wound dehiscence with a skin flap, hyperbaric and antibiotic therapy (Trimethoprim 800 mg — Sulfamethoxazole 160 mg).

The patient was referred to our department, three years after surgery, presenting two large local recurrences (17×13 cm and 16×13 cm axial plane diameters, respectively) (fig. 2). Due to the inefficacy of either chemotherapy or radiation therapy in chondrosarcoma, an external forequarter amputation was proposed, but the patient refused further surgeries. Therefore, considering the high degree of tumor vascularization, a selective arterial embolization was proposed as a palliative intervention.

A selective study of both the medial and the lateral femoral circumflex arteries was carried out (fig. 3, a, b). The exam was conducted using uroangiographic contrast medium (Omnipaque 350 — GE Healthcare). Flows and volumes varied according to the area examined. In the first session,

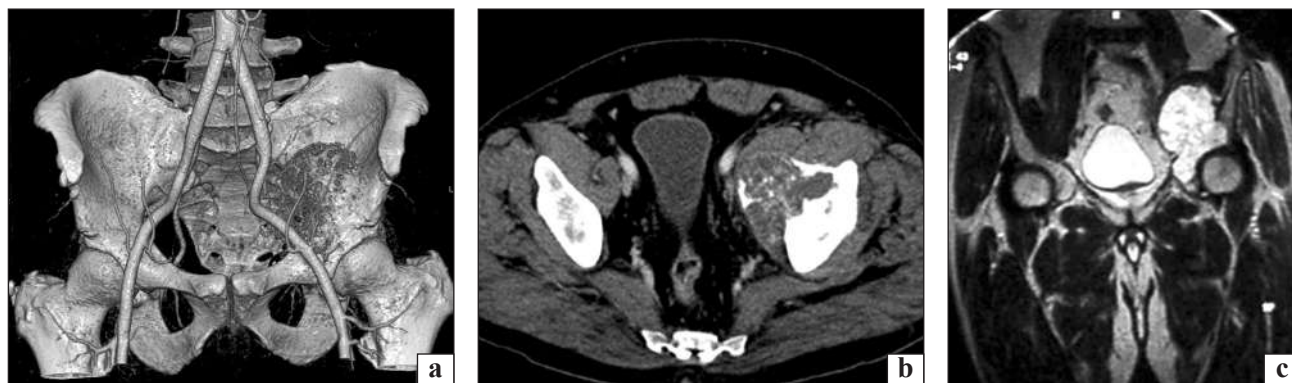

Fig. 1. CT 3D reconstruction highlighting the presence of a solid mass with well-defined sinuous margins, transverse diameter of 5.7 cm and cranio-caudal diameter of 9 cm, involving the acetabular area (a); CT scan (b) and MRI showing the expansive characteristics of the mass and its extensive invasion of the adjacent soft tissues (c)

2 ml of micro-embolizing particles (Contour — Boston Scientific 150–250 μm) were administered. The medium was injected into the lateral circumflex femoral artery, which appeared to be the main afferent artery of the largest lesion. Complete devascularization of the largest lesion was achieved as shown angiographically (fig. 3, c). Twenty days later, another angiographic study was performed in which a partial revascularization of the lesion was evident. More precisely, a few collateral branches of the femoral lateral circumflex artery were recanalized, showing nevertheless slowed blood flow. In addition, the medial circumflex femoral artery, the principal afferent artery of the smallest lesion, supplied a collateral circulation that contributed to the reperfusion of the previously embolized lateral circumflex arterial branches (fig. 4, a, b). In light of this finding, the decision to re-embolize the lateral circumflex femoral artery was taken. During the same session, the medial circumflex femoral artery was occluded. Careful attention was paid to spare the external pudendal artery, which is known to provide blood supply to the skin of the external genitalia. Three ml of micro-embolization (Contour — Boston Scientific 150–250 μm) were injected causing com-

plete devascularization of the two known lesions (fig. 4, a, b). As expected, the two largest masses were essentially unchanged in terms of size, but symptoms (pain, visceral compression) were significantly reduced. Four months later, a new arteriographic study showed partial reperfusion of the circles previously treated, and a further embolization of the medial and lateral circumflex femoral arteries was consequently performed with 2 ml of embolizing microparticles (Contour — Boston Scientific mean diameter 150–250 μm), obtaining a new total devascularization of the lesions.

After 3 months, the CT scan showed a partial reperfusion of the tumor. The medial mass was increased in size, while the more lateral mass remained almost unchanged. A new angiographic study showed a nearly complete reperfusion of all femoral arterial branches afferent to the lesions (fig. 5, a). A final embolization, of all arterial branches supplying vascularization to the tumor, was performed using acrylic (n-butyl-2-cyanoacrylate) glue (Glubran 2 — GEM) for the greater caliber vessels, and polyvinyl alcohol (PVA) microparticles (150–250 μm) for the smallest branches (fig. 5, b).

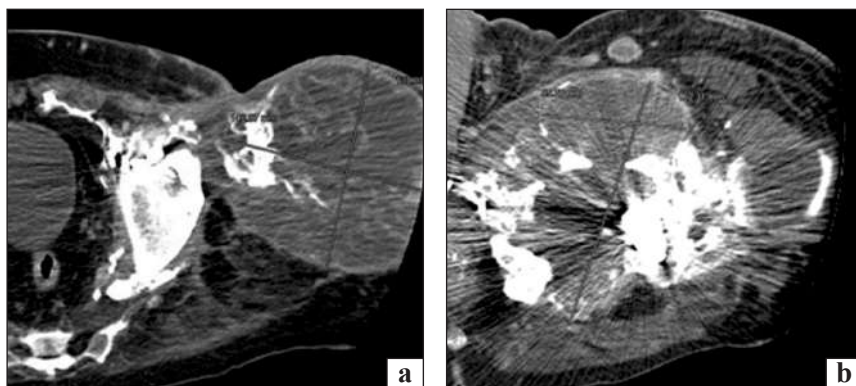


Fig. 2. Multi CT examination showing two voluminous expansive masses, with a high degree of vascularization, at the root of the left thigh (a, b)

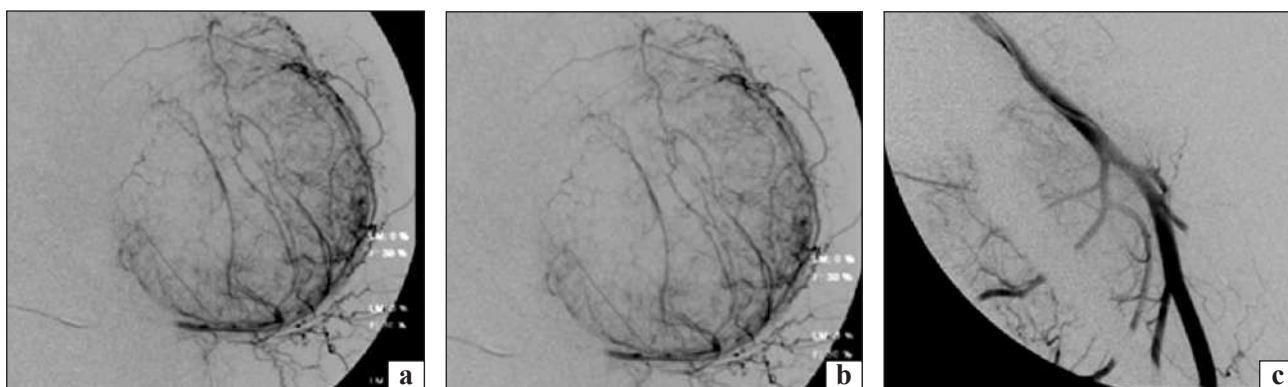


Fig. 3. Selective digital subtraction angiography (DSA) of the circumflex femoral arteries confirming the high degree of vascularization of the masses (a, b). Post-embolization DSA examination of the lateral circumflex femoral artery; note the complete devascularization of the bigger mass, laterally localized (c)

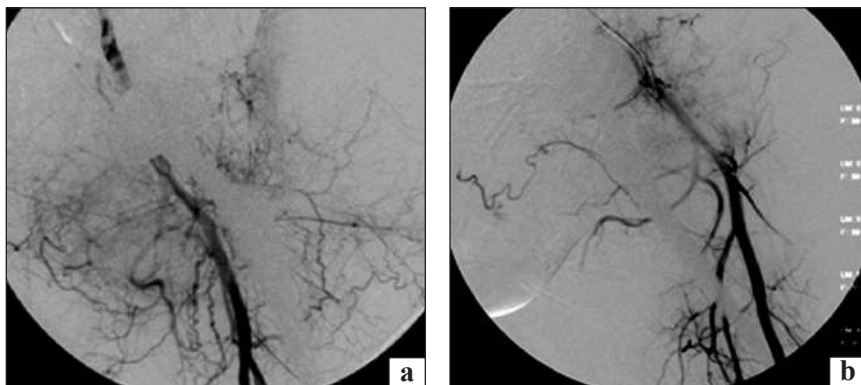


Fig. 4. Control with DSA examination twenty days after the embolization: partial reperfusion of the larger mass by a collateral arterial vessel sustained by medial circumflex arterial branches (a). A control after a further embolization demonstrates the complete devascularization of both lesions, with substantial sparing of the external pudendal arterial branches (b)

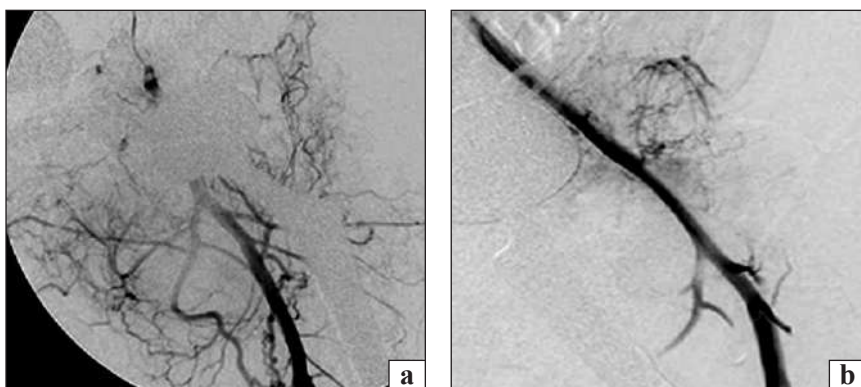

Fig. 5. DSA examination executed two months after the previous CT. Partial reperfusion of both the medial and lateral circumflex arterial branches (a). Angiographic control after further embolization: although good devascularization was achieved, a few arterial micro-vessels could not be occluded for lack of stable catheterization (b)

During follow-up the patient experienced a subjective benefit from the embolization cycles. In fact, the pain on the NRS scale (from 1 to 10) went from grade 5 to grade 3, despite the progressive increase of the diameter of the two masses. The patient died of disease 3 years after the onset of local recurrences; during this time period, he was pain free and ambulatory.

Discussion

The optimal strategy for the management of a chondrosarcoma of the pelvis is difficult to be established [3, 8, 10]. The main surgical challenge is the isolation of the large tumor mass without entering the lesion, in order to remove it en-bloc with wide margins. However, the risk of local recurrence remains high even after adequate surgical resection [3, 9]. The role of an aggressive surgical approach for recurrent tumors has been previously highlighted, whereas survival has been shown to be poor in patients where surgery is not a viable option [11].

Currently, non-invasive and percutaneous treatments are available for the palliative management of patients with bone tumors and selective arterial embolization is increasingly used both for its effectiveness and low invasiveness [12–17]. The rationale of embolization is to devascularize the lesion, inducing extensive necrosis in the neoplastic tissue.

While the treatment may be curative for benign forms [18–20], for malignant forms, such as chondrosarcoma, the intervention is only palliative and indicated if surgery would be too damaging and/or not radical [17, 21–23]. The effectiveness of the treatment is due to the occlusion of the most peripheral vessels, which supply the core of the tumor. To reach such small vessels, the use of «fluid» embolizing agents is required [16]. PVA microparticles, whose mean diameter is 200 microns, are able to occlude such small vessels, however, their use is characterized by a high risk of skin branch occlusion, with the development of ischemic skin lesions. The risk of skin lesion is significantly reduced by the use of an acrylic glue, diluted 1 : 3 with iodized oil (Lipiodol — Guerbet). With the use of an acrylic glue it is possible to limit embolization to the proximal larger vessels. Considering, nevertheless, that the occlusion will be irreversible, this agent should be used only by experienced radiologists, due to the high risk of permanent occlusion of non-targeted vessels [24, 25]. In the present report, the final procedure was performed using two agents: the acrylic glue was used for larger vessels, where the risk of reflux was low and a permanent embolization was needed; while the use of PVA was retained for the occlusion of smaller vessels, where a higher risk of reflux was considerable and with the objective of reaching the distal vascular core of the tumor.

Conclusions

In conclusion, embolization can be used effectively for palliation of vascularized high-grade chondrosarcomas of the pelvis. By serial hyper-selective catheterization and embolization of the pathologic feeding arteries with the most appropriate embolic agent, embolization can be expected to be successful in terms of symptom control and pain relief.

Conflict of interest. The authors declare the absence of conflict of interest.

References

- Chondrosarcomas revisited / A. F. Mavrogenis, M. Gambarotti, A. Angelini [et al.] // *Orthopedics*. — 2012. — Vol. 35 (3). — P. e379–e390. — DOI: 10.3928/01477447-20120222-30.
- Survival analysis of patients with chondrosarcomas of the pelvis / A. F. Mavrogenis, A. Angelini, G. Drago [et al.] // *The Journal of Surgical Oncology*. — 2013. — Vol. 108 (1). — P. 19–27. — DOI: 10.1002/jso.23351.
- Clinical outcome of central conventional chondrosarcoma / A. Angelini, G. Guerra, A. F. Mavrogenis [et al.] // *The Journal of Surgical Oncology*. — 2012. — Vol. 106 (8). — P. 929–937. — DOI: 10.1002/jso.23173.
- Surgical treatment and outcome of conventional pelvic chondrosarcoma / D. Donati, A. E. Ghoneimy, F. Bertoni [et al.] // *Journal of Bone and Joint Surgery. Br.* — 2005. — Vol. 87 (11). — P. 1527–1530. — DOI: 10.1302/0301-620X.87B11.16621.
- Hindquarter amputation for tumours of the musculoskeletal system / S. R. Carter, D. M. Eastwood, R. J. Grimer, R. S. Sneath // *Journal of Bone and Joint Surgery. Br.* — 1990. — Vol. 72 (3). — P. 490–493.
- Three-dimension-printed custom-made prosthetic reconstructions: from revision surgery to oncologic reconstructions / A. Angelini, G. Trovarelli, A. Berizzi [et al.] // *International Orthopaedics*. — 2019. — Vol. 43 (1). — P. 123–132. — DOI: 10.1007/s00264-018-4232-0.
- Hugate R. Jr. Pelvic reconstruction techniques / R. Hugate Jr., F. H. Sim // *Orthopedic Clinics of North America*. — 2006. — Vol. 37 (1). — P. 85–97. — DOI: 10.1016/j.ocl.2005.08.006.
- Malignant tumors of the pelvis: an outcome study / H. J. Mankin, F. J. Hornicek, H. T. Temple, M. C. Gebhardt // *Clinical Orthopaedics and Related Research*. — 2004. — № 425. — P. 212–217. — DOI: 10.1097/00003086-200408000-00030.
- The role of surgical margins in chondrosarcoma / J. D. Stevenson, M. K. Laitinen, M. C. Parry [et al.] // *European Journal of Surgical Oncology*. — 2018. — Vol. 44 (9). — P. 1412–1418. — DOI: 10.1016/j.ejso.2018.05.033.
- Long-term outcome of chondrosarcoma: a single institutional experience / S. Bindiganavile, I. Han, J. Y. Yun, H. S. Kim // *Cancer Research and Treatment*. — 2015. — Vol. 47 (4). — P. 897–903. — DOI: 10.4143/crt.2014.135.
- The treatment of locally recurrent chondrosarcoma: Is extensive further surgery justified? / A. Streitberger, H. Ahrens, G. Gosheger [et al.] // *Journal of Bone and Joint Surgery. Br.* — 2012. — Vol. 94 (1). — P. 122–127. — DOI: 10.1302/0301-620X.94B1.26876.
- Minimally invasive treatments of painful bone lesions: state of the art / A. Barile, F. Arrigoni, L. Zugaro [et al.] // *Medical Oncology*. — 2017. — Vol. 34 (4). — Article ID: 53. — DOI: 10.1007/s12032-017-0909-2.
- Breslau J. Preoperative embolization of spinal tumors / J. Breslau, J. M. Eskridge // *Journal of Vascular and Interventional Radiology*. — 1995. — Vol. 6 (6). — P. 871–875.
- Gangi A. Percutaneous bone tumor management / A. Gangi, X. Buy // *Seminars in Interventional Radiology*. — 2010. — Vol. 27 (2). — P. 124–126. — DOI: 10.1055/s-0030-1253511.
- Gottfried O. N. Embolization of sacral tumors / O. N. Gottfried, M. H. Schmidt, E. A. Stevens // *Neurosurgery Focus*. — 2003. — Vol. 15 (2). — P. E4.
- Embolization of bone tumors / A. F. Mavrogenis, G. Rossi, E. Rimondi [et al.] // *Orthopedics*. — 2011. — Vol. 34 (4). — P. 303–310. — DOI: 10.3928/01477447-20110228-20.
- Owen R. J. Embolization of musculoskeletal bone tumors / R. J. Owen // *Seminars in Interventional Radiology*. — 2010. — Vol. 27 (2). — P. 111–123. — DOI: 10.1055/s-0030-1253510.
- Embolization of benign and malignant bone and soft tissue tumors of the extremities / S. Boruban, T. Sancak, Y. Yildiz, Y. Saglik // *Diagnostic and Interventional Radiology*. — 2007. — Vol. 13 (3). — P. 164–171.
- Preoperative embolisation in benign bone tumour excision / V. N. Lee, M. Nithyananth, V. M. Cherian [et al.] // *Journal of Orthopaedic Surgery (Hong Kong)*. — 2008. — Vol. 16 (1). — P. 80–83. — DOI: 10.1177/230949900801600118.
- Selective arterial embolisation for bone tumours: experience of 454 cases / G. Rossi, A. F. Mavrogenis, E. Rimondi [et al.] // *Radiologia Medica*. — 2011. — Vol. 116 (5). — P. 793–808. — DOI: 10.1007/s11547-011-0670-0.
- Usefulness of transcatheter arterial embolization prior to excision of hypervascular musculoskeletal tumors / S. Iwamoto, S. Takao, H. Nose [et al.] // *The Journal of Medical Investigation*. — 2012. — Vol. 59 (3–4). — P. 284–288.
- Palliative embolisation for advanced bone sarcomas / A. F. Mavrogenis, G. Rossi, G. Altimari [et al.] // *Radiologia Medica*. — 2013. — Vol. 118 (8). — P. 1344–1359. — DOI: 10.1007/s11547-012-0868-3.
- Pelvic chondroblastoma in an adolescent. New treatment approach / G. Rico-Martinez, L. Linares-Gonzalez, E. Delgado-Cedillo [et al.] // *Acta Ortopédica Mexicana*. — 2011. — Vol. 25 (6). — P. 389–395.
- Palliative treatments for advanced osteosarcoma / A. F. Mavrogenis, G. Rossi, E. Palmerini [et al.] // *J. BUON*. — 2012. — Vol. 17 (3). — P. 436–445.
- Preoperative transarterial embolization using gelatin sponge for hypervascular bone and soft tissue tumors in the pelvis or extremities / M. Shimohira, K. Nagai, T. Hashizume [et al.] // *Acta Radiologica*. — 2016. — Vol. 57 (4). — P. 457–462. — DOI: 10.1177/0284185115590435.

ПАЛІАТИВНА ЕМБОЛІЗАЦІЯ АРТЕРІЙ І ВЕН У РАЗІ РЕЦИДИВІВ ХОНДРОСАРКОМИ ТАЗА

К. Біз¹, А. Ангеліні¹, А. Крїмі¹, Дж. Трoвареллі¹, В. Ігумену¹, А. Мавроженіс², П. Руджієрі¹

¹ Кафедра ортопедії та ортопедичної онкології, Університет Падуї, Італія

² Афі́нський Національний університет ім. Каподістрії, Перша кафедра ортопедії, Греція

- ✉ Carlo Biz, Doctor of Orthopaedics and Traumatology: carlo.biz@unipd.it
- ✉ Andrea Angelini, Doctor of Orthopaedics and Traumatology: andrea.angelini@unipd.it
- ✉ Alberto Crimi, Doctor of Orthopaedics and Traumatology: albe.crim@gmail.com
- ✉ Giulia Trovarelli, Doctor of Orthopaedics and Traumatology: giuliatrovarelli87@gmail.com
- ✉ Vasilios Igoumenou, Doctor of Orthopaedics and Traumatology: vasigou@med.uoa.gr
- ✉ Andreas Mavrogenis, Doctor of Orthopaedics and Traumatology: afm@otenet.gr
- ✉ Pietro Ruggieri, Doctor of Orthopaedics and Traumatology: pietro.ruggieri@unipd.it

ДО УВАГИ СПЕЦІАЛІСТІВ

**ДУ «Інститут патології хребта та суглобів ім. проф. М. І. Ситенка НАМН України»
проводить післядипломну підготовку фахівців на курсах інформації та стажування
з актуальних питань ортопедії та травматології
(ліцензія Міністерства освіти і науки України АЕ № 285527 від 27.11.2013)**

Курси для середнього медичного персоналу:

Назва
Лікувальний масаж

Керівник
К. м. н. Стауде В. А.

Телефон для довідок: (057) 725-14-77