

НА ДОПОМОГУ ЛІКАРЕВІ-ПРАКТИКУ. ЛЕКЦІЇ

УДК 616-001.45.515-036.12.9-089:615.281

DOI: <http://dx.doi.org/10.15674/0030-59872023362-68>

Approaches to surgical treatment and antibacterial therapy in patients with chronic infection after war injuries

A. Trampuz¹, O. Pidgaiska², V. Filipenko², K. Romanenko², O. Maruschack²

¹ Biofilm Research Laboratory Center for Musculoskeletal Surgery Charite–Universitätsmedizin, Berlin. Germany

² Sytenko Institute of Spine and Joint Pathology National Academy of Medical Sciences of Ukraine, Kharkiv

Fracture-related infection following orthopedic surgery, especially in cases of war-related trauma, represents a grave complication. The injuries sustained in war often entail severe damage to soft tissues, including significant impairment of vessels, nerves, tendons, muscles, and result in substantial bone defects. Complicating matters further, these infections often involve multidrug-resistant pathogens, making effective treatment a significant challenge. Optimal management of patients with combat-related trauma and signs of infection necessitates specialized care in dedicated centers. The approach to treatment should be guided by a well-defined algorithm that incorporates appropriate surgical interventions alongside systemic and localized antibiotic administration. In instances where chronic infection manifests after war-related injuries and specific causative agents are not definitively identified, initiating empiric therapy is advisable. A combination of meropenem, colistin, and vancomycin can be a suitable choice for initial treatment. Subsequently, once the causative microbes are identified, targeted treatment can be prescribed based on the susceptibility patterns. This article delves into the primary pathogens commonly found in war-related wounds and provides effective antibiotic regimens based on the specific microorganisms. One promising approach for managing severe war injuries is suppressive antibiotic therapy, which enhances the prospects of successful treatment. The comprehensive strategy outlined here aims to mitigate the serious risks posed by fracture-related infections in the context of war-induced trauma, ultimately improving patient outcomes and prognosis.

Інфекція внаслідок переломів після ортопедичного втручання, у випадках травмування під час бойових дій, є серйозним ускладненням. Поранення, отримані в таких умовах, часто супроводжуються важкими ураженнями м'яких тканин, зокрема значними uszkodженнями судин, нервів, сухожилок, м'язів і великих кісткових дефектів. До більших ускладнень призводить наявність в інфекції патогенів, які є стійкими до основних груп антибіотиків, що робить ефективне лікування серйозною проблемою. Лікування пацієнтів із бойовими травмами й ознаками інфекції вимагає ретельного підходу і їхнього перебування в спеціалізованих ортопедо-травматологічних центрах. Підхід до лікування має ґрунтуватись на чітко визначеному алгоритмі, який включає відповідні хірургічні втручання поряд із системним та локалізованим призначенням антибіотиків. У випадках, коли хронічна інфекція проявляється після поранень, унаслідок бойових дій, і конкретні збудники остаточно не ідентифіковані, доцільно почати емпіричну терапію. Комбінація меропенему, колістину та ванкоміцину може бути відповідним вибором для початкового лікування. Згодом, коли мікроби-збудники виявлені, можна призначати цілеспрямоване лікування на основі антибіотикограми. Розглянуто основні патогени, які, зазвичай, зустрічаються під час поранень, і наведено ефективні схеми використання антибіотиків на основі конкретних мікроорганізмів. Одним з ефективних підходів до лікування важких військових поранень є супресивна антибіотикотерапія, яка підвищує перспективи успішного лікування. Комплексна стратегія, викладена нами, має на меті пом'якшити серйозні ризики, через інфекційні ускладнення, у контексті травми, спричиненої війною, і покращити результати та прогноз для пацієнтів. Ключові слова. Інфекція, антибіотикотерапія, бойова травма.

Keywords. Infection, antibiotic therapy, combat trauma

© Trampuz A., Pidgaiska O., Filipenko V. et al., 2023

Infectious complications following orthopedic surgery pose a significant threat, potentially resulting in fracture nonunion, loss of function, and in severe cases, amputation. The incidence of post-traumatic infection varies based on the type of fracture, with reported rates around 1–2 % for closed fractures and exceeding 30 % for open Gustilo-Anderson type III tibial fractures [1–3]. The success of treatment, contingent on injury severity, typically ranges from 70–90 %, but recurrence of infection occurs in 6–9 % of patients [4]. Notably, the frequency of infectious complications in open fractures escalates in alignment with the degree of soft tissue damage [5].

In the context of war, injuries to the musculoskeletal system are often accompanied by extensive damage to soft tissues, bone defects, compromised blood circulation, and nerve injuries. Moreover, the wounds are contaminated with a variety of microorganisms from the ground and the victim's skin, making infection a significant concern. The fundamental principles guiding the treatment of open wounds to the musculoskeletal system encompass irrigation (washing), sanitization, soft tissue management, bone fragment stabilization, and the early administration of broad-spectrum antibiotics. This is followed by precise identification of the microbial agents involved, enabling targeted antibiotic therapy. Additionally, modern infection management strategies, such as the Masquelet technique, intramedullary canal irrigation, and the use of rods coated with antibiotic bone cement, have been valuable additions to the armamentarium [6]. In the case of open fractures accompanied by soft tissue damage, initial treatment often involves preemptive empirical use of broad-spectrum antibiotics. Once the specific causative agent is identified, a switch to targeted antibiotic therapy is warranted. Given the circumstances of war injuries, prophylactic antibiotic use is not a viable option, as it is understood that foreign bodies from grenades or bullets that have entered and injured the musculoskeletal system are already contaminated. In many cases, patients are referred to specialized orthopedic and trauma centers after undergoing multiple surgical interventions. These individuals often exhibit signs of chronic infection, which can be exacerbated by the presence of metal implants used to stabilize bone fragments. The implants can contribute for infection, particularly due to the formation of bacterial biofilms. Notably, bacteria within biofilms exhibit significantly higher resistance to antibiotic therapy — up to 10,000 times more resistant compared to their free-floating planktonic counterparts [7]. The multi-layered structure of the biofilm offers protection against both the im-

mune system and antibiotics, comprising a metabolically active outer layer that facilitates bacterial dissemination through the release of planktonic variants and an inner layer with reduced activity [8].

Following the principles of treating infectious complications, biofilm eradication therapy methods are crucial. This includes thorough debridement involving the removal of the metal implant, potential replacement, or the utilization of a spacer. Rational antibiotic therapy including anti-biofilm drugs is also pivotal and has shown promise in enhancing treatment effectiveness [9, 10]. Localized antibiotic therapy directly at the site of infection holds significant potential in achieving these objectives. By effectively disrupting the biofilm, treatment success rates can be heightened, enabling a broader range of less invasive surgical interventions and, in some cases, obviating the need for additional surgeries.

In this article, drawing upon our experience at the Center of Musculoskeletal Surgery in the Charite University Medicine Berlin, Germany, and at the Sytenko Institute of Spine and Joint Pathology in Kharkiv, Ukraine, we will delineate the primary surgical approaches for this patient category. Additionally, we will outline the antibiotic groups that should be employed based on the identified pathogens, shedding light on optimal treatment strategies.

Regrettably, the experience gained by orthopedic and trauma physicians during the treatment of patients with the consequences of war injuries has shown that in most cases the main causative agents of infectious complications are gram-negative pathogens that have proven resistant to most of the antibacterial drug groups. They are called multiresistant gram-negative pathogens (MRGNP). According to the German classification, these pathogens belong to the 3rd or 4th type of MRGNP, which means that they are not more sensitive to the main four groups of antibiotics: piperacillin/tazobactam; third generation cephalosporins; fluoroquinolones; carbapenems [12, 13]. Another problem of such infectious complications is that the infection is polymicrobial in most cases, which greatly complicates the selection of antibiotics. The main causative organisms are *Klebsiella pneumoniae*, *Acinetobacter baumannii* and *Pseudomonas aureginosa*. *Escherichia coli*, *Enterobacte* are also common, and together with gram-negative flora, staphylococci and fungal infection are often present. When choosing tactics for surgical treatment, we use an algorithm that was developed by prof. A. Trampuz (Figure) for the treatment of patients with implant-associated infection.

Considering the unique challenges posed by war injuries, particularly those manifesting chronic infectious processes and extensive soft tissue defects, a strategic approach involving multiple debridements is essential. This approach entails the removal of necrotic tissues, repeated thorough wound irrigation using pulse lavage, application of local antiseptics, opening of the bone marrow canal with meticulous washing, and the removal of foreign bodies. These interventions collectively serve to reduce the bacterial cell concentration within the wound significantly. The mechanical clearance achieved through the removal of the metal implant not only aids in biofilm eradication but also enhances blood circulation, creating a conducive environment for systemic antibiotics to be more effective. The utilization of Vacuum-Assisted Closure (VAC) therapy, combined with systemic administration of wide-spectrum antibiotics, is instrumental in closing soft tissue defects. However, it's important to note that the use of VAC therapy can sometimes lead to the development of gram-negative and fungal infections. As a result, caution is warranted, and concurrent treatment involving VAC therapy, internal metal implants, and local antibiotic

usage is contraindicated. Only after successful skin graft engraftment can a transition to comprehensive osteosynthesis be considered, ensuring a systematic and well-considered approach to treatment.

All patients who are started on intravenously antibiotics should be tested for baseline inflammatory markers, full blood count, electrolytes, and liver and renal function tests and should be monitored at least once weekly (depending on host status) in the acute phase of their illness as common side effects of high-dose intravenously antibiotics include bone marrow suppression, hepatitis, and nephritis.

An essential consideration in devising an effective treatment strategy for chronic infections in patients with a history of war-related injuries is the challenging scenario where prior surgical interventions did not succeed in achieving fracture healing due to the persistent infectious process. Furthermore, the presence of multidrug-resistant pathogens compounds the complexity of treatment. This combination of factors often characterizes an infection that proves difficult to treat. In such challenging cases, a staged surgical treatment approach, coupled with suppressive therapy, is a prudent course of action.

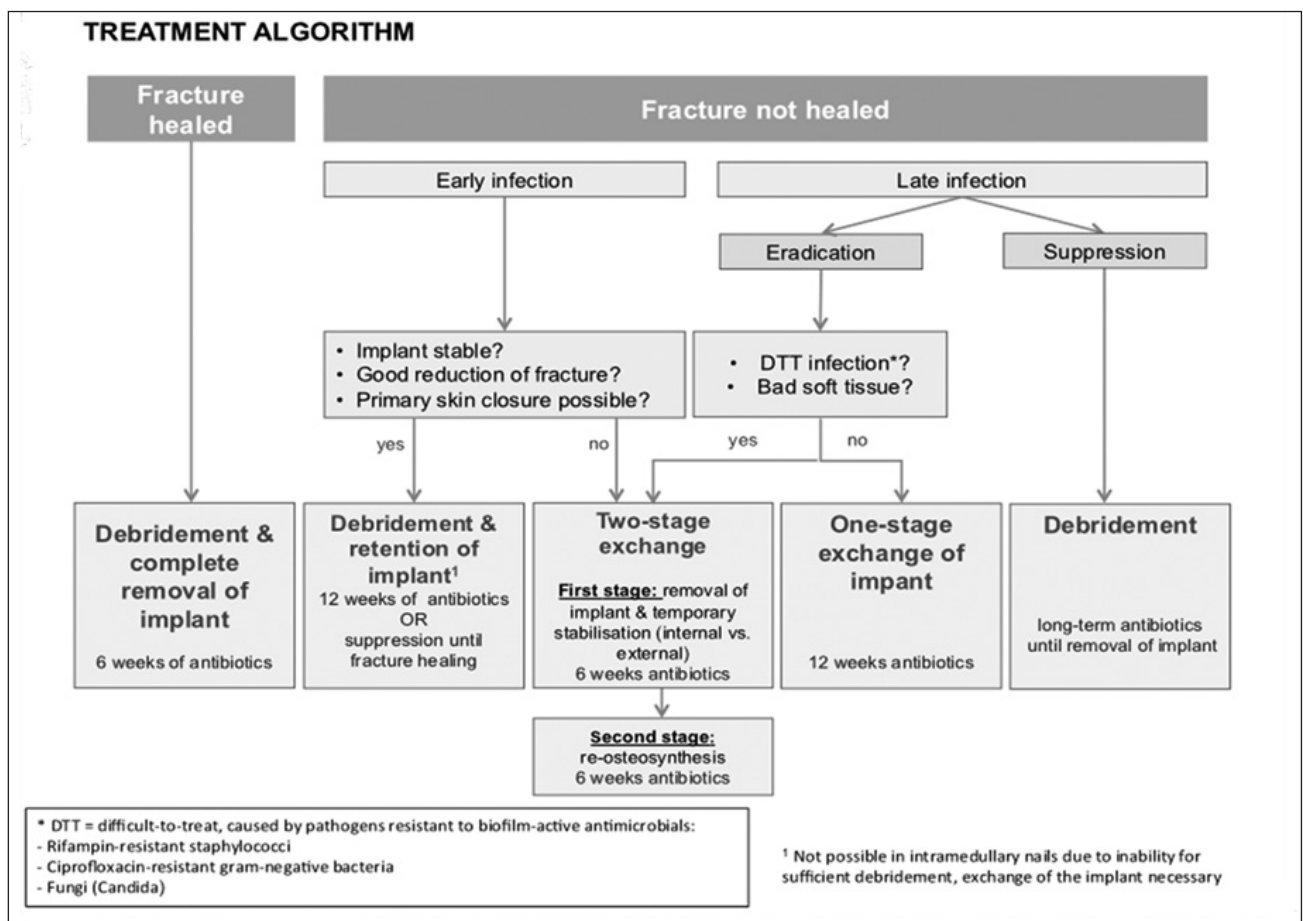


Figure. Algorithm of surgical treatment of patients with infectious complications after osteosynthesis

Long-term systemic suppressive antibiotic therapy assumes paramount importance as it offers a means to regain control over the infection and ultimately facilitates fracture union.

Drawing from our collective clinical experience, when faced with signs of chronic infection and lacking specific data on the causative agents, prescribing an empiric therapy comprising a combination of meropenem, colistin, and vancomycin is advisable. Despite the prevalence of gram-negative flora in the wound, gram-positive flora may indeed «hide» behind the dominant gram-negative pathogens, and they might not be initially detected during bacteriological examination. Accurate antibiotic dosage is of great importance in ensuring efficacy. Meropenem is prescribed at a dosage of 1.0 gram three times a day, colistin at 3 million units three times a day, and vancomycin at 2 grams twice a day for an initial three-day period to achieve a therapeutic effect. Subsequently, vancomycin dosage is reduced to 1 gram twice a day while meticulously monitoring renal function parameters for dose adjustments.

1. *Pseudomonas aeruginosa*. *Pseudomonas aeruginosa* presents a formidable challenge for eradication due to its inherent resistance mechanisms. The bacterium possesses a high level of internal resistance to a broad spectrum of antibiotics. This resistance is attributed to factors such as the limited permeability of its outer membrane, efflux systems or pumps that expel antibiotics from the cell, and the production of enzymes like beta-lactamases that deactivate antibiotics.

Ceftazidime and Cefepime: Ceftazidime and cefepime, both belonging to the 4th generation cephalosporin series, are highly effective against *Pseudomonas aeruginosa*. Ceftazidime, in particular, was developed specifically for combatting this pathogen. They are primarily active against gram-negative bacteria. The recommended dosage is a maximum of 2 grams three times a day.

Colistin: Colistin is another potent antibiotic effective against *Pseudomonas aeruginosa*. It is often recommended to combine colistin with meropenem or fosfomycin to achieve a synergistic effect, enhancing its efficacy. However, caution is necessary when using colistin due to its association with a high risk of nephrotoxicity. Hence, careful monitoring of renal function and serum dosages is essential. Colistin can also be beneficial for local treatment in a wound or as an addition to a cement spacer.

When dealing with a wound that is concurrently infected with *Pseudomonas aeruginosa* and *Staphylococcus aureus*, it indeed presents a challenging sce-

nario for effective eradication. The presence of both these pathogens can complicate treatment and necessitate a thoughtful and strategic approach, which may include considering suppressive therapy due to the difficulty in complete eradication.

2. *Enterococci*. When dealing with an infection caused by a group of enterococcal pathogens sensitive to penicillin, the recommended treatment involves administering ampicillin at a dosage of 2 grams four times a day, in combination with intravenous gentamicin at 240 mg once daily for a duration of 2–3 weeks. The gentamicin dosage is adjusted based on body weight, typically at 3 mg/kg. Subsequently, a transition to oral administration of amoxicillin at 1.0 g three times a day, along with doxycycline at 100 mg twice daily, can be considered.

In cases where enterococcal strains are resistant to penicillin, an alternative treatment regimen involving vancomycin at a dosage of 1.0 g twice daily in conjunction with daptomycin once daily at a dose of 10 mg/kg of body weight intravenously is recommended. For later stages of oral therapy, linezolid at 600 mg twice a day can be used. However, it's crucial to limit the duration of linezolid treatment to no more than 4 weeks to mitigate potential irreversible side effects, such as damage to peripheral nerves, vision loss, and impaired bone marrow function, including a reduction in leukocytes, erythrocytes, and platelets.

In cases where the causative agent displays resistance to vancomycin, it is advisable to avoid using metal implants. Alternatively, suppressive therapy using doxycycline or daptomycin can be considered based on the pathogen's sensitivity profile.

Enterococcus faecalis often causes a chronic infection that occurs without a general temperature reaction, almost no pain in the affected area, and is very often associated with a cardiac implant, endocarditis, and chronic prostatitis. Ciprofloxacin in dosage 750 mg twice a day is only effective against *Enterococcus faecalis*, but not *Enterococcus faecium*.

3. *Enterobacterales*. In the case of detection of another gram-negative enterobacterium, treatment should be carried out with ciprofloxacin in a dosage of 750 mg twice a day. If there is resistance to ciprofloxacin, depending on the sensitivity, choose meropenem, or colistin, or fosfomycin.

4. *Streptococcus*. Infection that is caused by *Streptococcus*. Streptococcal infection accounts for 10 %, mainly spread by hematogenous route. Trampuz's in vitro studies have shown that streptococci can form a biofilm, but the administration of rifampicin is not effective [14]. This pathogen is characterized by rapid spread in soft tissues and fascia in most cases, rather

than the formation of abscesses or biofilms. In most cases, relapse of infection occurs within the first year after implantation. A streptococcal infection that is extremely difficult to eradicate. Streptococci do not develop resistance to amoxicillin, so we can prescribe it in high doses without fear of overdose or resistance. A possible way to treat streptococcal infection is suppressive therapy with amoxicillin for 1–3 years at a dosage of 1.0 g three times a day. Other drugs that are effective are penicillin, ceftriaxone, and doxycycline [15].

5. *Staphylococci*. *Staphylococcus*, particularly *Staphylococcus aureus* (including methicillin-sensitive *Staphylococcus aureus* — MSSA and methicillin-resistant *Staphylococcus aureus* — MRSA), is a common causative organism in bone and joint infections, including those associated with fractures. In open fractures *S. aureus* is the most commonly isolated pathogen regardless of time to onset, followed by *S. epidermidis* and non-epidermidis/non-lugdunensis coagulase-negative staphylococci (CoNS) [16, 17].

Treatment of methicillin-sensitive strains is carried out with the use of cefazolin 2 grams three times a day or fosfomycin in a dosage of 5 grams three times a day. It is possible to carry out therapy using both of these drugs. As in other cases, the treatment lasts for 2 weeks of intravenous administration with subsequent transition to antibacterial drugs that have anti-biofilm activity. In cases of staphylococcus resistance to methicillin, vancomycin is used at 1 gram twice a day or daptomycin at 8 mg/kg once a day. Also, both of these drugs can be supplemented with fosfomycin. Coagulase-negative staphylococci such as *Staphylococcus epidermidis* are treated like MRSA if they are methicillin-resistant (MRSE). In severe cases of rifampicin-resistant staphylococcus, the above antibiotics are used as suppressive therapy for a year or longer, depending on the sensitivity. For suppressive therapy of *S. aureus*, it is better to use cotrimoxazole (Biseptol) in a dosage of 960 mg three times a day. This drug counteracts a wide range of pathogens, it covers all gram-positive and gram-negative strains, but does not have an anti-biofilm effect. If *S. epidermalis* or *S. hominis* are isolated from the wound, then these microorganisms are present only in the presence of a metal in the place of fracture, if metal implants are removed, it is possible to quickly eradicate these pathogens. Monotherapy with fluoroquinolones is not recommended for staphylococcal infections because of the rapid emergence of resistance and high treatment failure rate [18].

6. *Fungi*. Fungal infection is one of the most difficult to treat. With a fungal infection, a three-stage replacement is more often performed, and if there is resistance to fluconazole, one should think about suppressive therapy for a year or not to install metal implants, because voriconazole is the only drug available at that time. For the treatment of fungal infection, caspofungin is used in a dosage of 70 mg intravenously and fluconazole 400 mg per day orally.

7. *Anaerobes*. In the group of gram-positive anaerobes, *Cutibacterium* (previously *Propionibacterium*) *acnes* is most frequently isolated. We recommend starting with ceftriaxone 2 grams a day, followed by oral treatment of rifampicin in combination with amoxicillin (1gram three times a day), doxycycline (100 mg 2 times a day), or quinolones (levofloxacin 500 mg 2 times a day). Gram-negative anaerobes should be treated with IV ampicillin/sulbactam (3 grams three times a day) followed by oral metronidazole (500 mg three times a day).

Among the groups of antibacterial drugs that are more often used for suppressive therapy:

- with staphylococcal infection: cotrimoxazole, doxycycline, clindamycin;
- with streptococcal infection: amoxicillin, clindamycin, levofloxacin;
- with enterococcal infection: amoxicillin, linezolid
- with anaerobic infection: clindamycin, amoxicillin, metronidazole;
- with gram-negative pathogens: ciprofloxacin, cotrimoxazole.

To combat biofilm formation, especially after a two-stage or one-stage metal implant replacement, the use of antibiotics with anti-biofilm properties is crucial. Here are some important considerations:

Rifampicin is effective in countering biofilm formation. The recommended oral dosage is 300–450 mg twice a day or 600–900 mg once daily. It should commence after debridement and once the wound has sealed. Given the risk of superinfection with rifampicin-resistant strains, combination therapy is essential. Rifampicin should be used in conjunction with drugs like ciprofloxacin, levofloxacin, or cotrimoxazole to mitigate resistance development. Monitoring liver function through tests at baseline and subsequent assessments if there are clinical concerns is advisable due to the potential for liver-related side effects.

Other Antibiotics with Anti-biofilm Properties: Ciprofloxacin, Ceftriaxone, Ampicillin/Amoxicillin, Fosfomycin, Gentamicin.

Utilizing antibiotics with anti-biofilm properties is a critical aspect of preventing and managing bio-

film-associated infections, particularly in the context of metal implant replacements. However, the prudent use of these antibiotics, considering their potential side effects and the risk of resistance development, is crucial. Collaboration with infectious disease specialists and regular monitoring of patient response and resistance patterns can optimize the use of these antibiotics for effective treatment.

Conclusions

The treatment of patients with chronic infection after osteosynthesis of fractures resulting from war injuries is a complex task and requires combined efforts of orthopaedics, traumatologists, infectious diseases physicians, and plastic surgeons. The chronic infections associated with war-related fractures often entail long-term non-union of the fracture and the presence of bone and soft tissue defects. A feature of chronic infection in these cases is the prevalence of multiresistant, predominantly gram-negative pathogens. Furthermore, these infections frequently manifest as polymicrobial. The treatment approach centers on a carefully sequenced series of surgical interventions and the meticulous selection of antibacterial therapy. In instances where the infection proves difficult to eradicate, particularly when dealing with multi-resistant pathogens and limited soft tissue coverage for wound surfaces, long-term suppressive therapy becomes a viable strategy. This extended suppressive therapy aims to gain control over the infection, allowing the necessary time for the fracture to heal. The collaboration and expertise of a multidisciplinary team are essential in tailoring a comprehensive treatment plan for these patients. Careful consideration of surgical interventions, selection of appropriate antibiotics, and the judicious use of suppressive therapy, when warranted, form the cornerstones of effectively managing chronic infections post-osteosynthesis in war-related fractures.

Conflict of interest. The authors declare the absence of conflict of interest.

References

- Metsemakers, W.-J., Onsea, J., Neutjens, E., Steffens, E., Schuermans, A., McNally, M., & Nijs, S. (2017). Prevention of fracture-related infection: a multidisciplinary care package. *International Orthopaedics*, *41* (12), 2457–2469. <https://doi.org/10.1007/s00264-017-3607-y>
- Ktistakis, I., Giannoudi, M., & Giannoudis, P. V. (2014). Infection rates after open tibial fractures: Are they decreasing? *Injury*, *45* (7), 1025–1027. <https://doi.org/10.1016/j.injury.2014.03.022>
- Walter, N., Rupp, M., Lang, S., & Alt, V. (2021). The epidemiology of fracture-related infections in Germany. *Scientific Reports*, *11* (1). <https://doi.org/10.1038/s41598-021-90008-w>
- Bezstarosti, H., Van Lieshout, E. M. M., Voskamp, L. W., Kortram, K., Obremskey, W., McNally, M. A., Metsemakers, W. J., & Verhofstad, M. H. J. (2018). Insights into treatment and outcome of fracture-related infection: a systematic literature review. *Archives of Orthopaedic and Trauma Surgery*, *139* (1), 61–72. <https://doi.org/10.1007/s00402-018-3048-0>
- Lu, V., Zhang, J., Patel, R., Zhou, A. K., Thahir, A., & Krkovic, M. (2022). Fracture Related Infections and Their Risk Factors for Treatment Failure — A Major Trauma Centre Perspective. *Diagnostics*, *12* (5), 1289. <https://doi.org/10.3390/diagnostics12051289>
- Steinmetz, S., Wernly, D., Moerenhout, K., Trampuz, A., & Borens, O. (2019). Infection after fracture fixation. *EFORT Open Reviews*, *4* (7), 468–475. <https://doi.org/10.1302/2058-5241.4.180093>
- Rabin, N., Zheng, Y., Opoku-Temeng, C., Du, Y., Bonsu, E., & Sintim, H. O. (2015). Biofilm formation mechanisms and targets for developing antibiofilm agents. *Future Medicinal Chemistry*, *7* (4), 493–512. <https://doi.org/10.4155/fmc.15.6>
- Davies, D. (2003). Understanding biofilm resistance to antibacterial agents. *Nature Reviews Drug Discovery*, *2* (2), 114–122. <https://doi.org/10.1038/nrd1008>
- Metsemakers, W.-J., Morgenstern, M., Senneville, E., Borens, O., Govaert, G. A. M., Onsea, J., Depypere, M., Richards, R. G., Trampuz, A., Verhofstad, M. H. J., Kates, S. L., Raschke, M., McNally, M. A., & Obremskey, W. T. (2019). General treatment principles for fracture-related infection: recommendations from an international expert group. *Archives of Orthopaedic and Trauma Surgery*, *140* (8), 1013–1027. <https://doi.org/10.1007/s00402-019-03287-4>
- Depypere, M., Kuehl, R., Metsemakers, W.-J., Senneville, E., McNally, M. A., Obremskey, W. T., Zimmerli, W., Atkins, B. L., & Trampuz, A. (2020). Recommendations for Systemic Antimicrobial Therapy in Fracture-Related Infection. *Journal of Orthopaedic Trauma*, *34* (1), 30–41. <https://doi.org/10.1097/bot.0000000000001626>
- Steadman, W., Chapman, P. R., Schuetz, M., Schmutz, B., Trampuz, A., & Tetsworth, K. (2023). Local Antibiotic Delivery Options in Prosthetic Joint Infection. *Antibiotics*, *12* (4), 752. <https://doi.org/10.3390/antibiotics12040752>
- Hygienemaßnahmen bei Infektionen oder Besiedlung mit multiresistenten gramnegativen Stäbchen. (2012). *Bundesgesundheitsblatt - Gesundheitsforschung-Gesundheitsschutz*, *55* (10), 1311–1354. <https://doi.org/10.1007/s00103-012-1549-5>
- Magiorakos, A. P., Srinivasan, A., Carey, R. B., Carmeli, Y., Falagas, M. E., Giske, C. G., Harbarth, S., Hindler, J. F., Kahlmeter, G., Olsson-Liljequist, B., Paterson, D. L., Rice, L. B., Stelling, J., Struelens, M. J., Vatopoulos, A., Weber, J. T., & Monnet, D. L. (2012). Multidrug-resistant, extensively drug-resistant and pandrug-resistant bacteria: an international expert proposal for interim standard definitions for acquired resistance. *Clinical Microbiology and Infection*, *18* (3), 268–281. <https://doi.org/10.1111/j.1469-0691.2011.03570.x>
- Akgün, D., Trampuz, A., Perka, C., & Renz, N. (2017). High failure rates in treatment of streptococcal periprosthetic joint infection. *The Bone & Joint Journal*, *99-B* (5), 653–659. <https://doi.org/10.1302/0301-620x.99b5.bjj-2016-0851.r1>
- Renz, N., Rakow, A., Müller, M., Perka, C., & Trampuz, A. (2019). Long-term antimicrobial suppression prevents treatment failure of streptococcal periprosthetic joint infection. *Journal of Infection*, *79* (3), 236–244. <https://doi.org/10.1016/j.jinf.2019.06.015>
- Wang, B., Xiao, X., Zhang, J., Han, W., Hersi, S. A., & Tang, X. (2021). Epidemiology and microbiology of fracture-related infection: a multicenter study in Northeast China. *Journal of Orthopaedic Surgery and Research*, *16* (1). <https://doi.org/10.1186/s13018-021-02629-6>
- Depypere, M., Sliepen, J., Onsea, J., Debaveye, Y., Govaert, G. A. M., IJpma, F. F. A., Zimmerli, W., & Metsemakers, W.-

- J. (2022). The Microbiological Etiology of Fracture-Related Infection. *Frontiers in Cellular and Infection Microbiology*, 12. <https://doi.org/10.3389/fcimb.2022.934485>
18. Osmon, D. R., Berbari, E. F., Berendt, A. R., Lew, D., Zimmerli, W., Steckelberg, J. M., Rao, N., Hanssen, A., & Wilson, W. R. (2012). Diagnosis and Management of Prosthetic Joint Infection: Clinical Practice Guidelines by the Infectious Diseases Society of America. *Clinical Infectious Diseases*, 56 (1), e1–e25. <https://doi.org/10.1093/cid/cis803>
19. Widmer, A. F., Gaechter, A., Ochsner, P. E., & Zimmerli, W. (1992). Antimicrobial treatment of orthopedic implant-related infections with Rifampin combinations. *Clinical Infectious Diseases*, 14 (6), 1251–1253. <https://doi.org/10.1093/clinids/14.6.1251>
20. Sendi, P., & Zimmerli, W. (2012). Antimicrobial treatment concepts for orthopaedic device-related infection. *Clinical Microbiology and Infection*, 18 (12), 1176–1184. <https://doi.org/10.1111/1469-0691.12003>

Стаття надійшла до редакції: 25.08.2023

ПІДХОДИ ДО ХІРУРГІЧНОГО ЛІКУВАННЯ ТА АНТИБАКТЕРІАЛЬНОЇ ТЕРАПІЇ ХВОРИХ НА ХРОНІЧНУ ІНФЕКЦІЮ ПІСЛЯ БОЙОВИХ ПОРАНЕНЬ

А. Трампуш¹, О. Підгайська², В. Філіпенко², К. Романенко², О. Марушак²

¹ НДЛБ Центр хірургії опорно-рухового апарату Charite–Universitätsmedizin. Берлін. Німеччина

² ДУ «Інститут патології хребта та суглобів ім. проф. М. І. Ситенка НАМН України», Харків

✉ Andrej Trampuz, MD, Prof.: ed.etirahc@zupmart.jerdna

✉ Olga Pidgaiska, MD, PhD in Traumatology and Orthopaedics: podgayo@yahoo.com

✉ Volodymyr Filipenko, MD, Prof. in Orthopaedics and Traumatology: filipenko1957@gmail.com

✉ Kostiantyn Romanenko, MD, PhD in Traumatology and Orthopaedics: konstantin.romanenko@gmail.com

✉ Olexii Marushchak, MD: dr.marushchak@yahoo.com